

Seeing Spots: Rashes in Children

Teresa S. Wright, MD, FAAD, FAAP
LeBonheur Children's Hospital

Disclosures

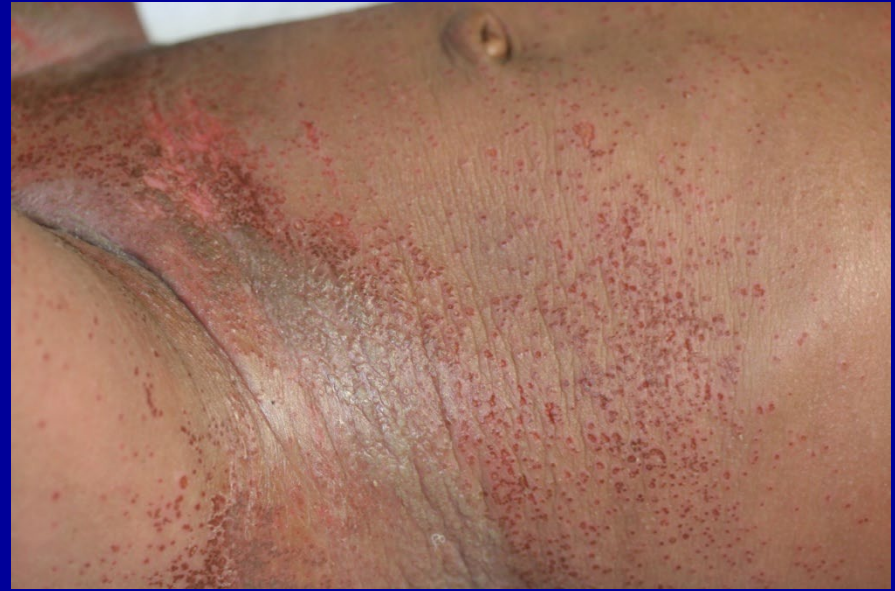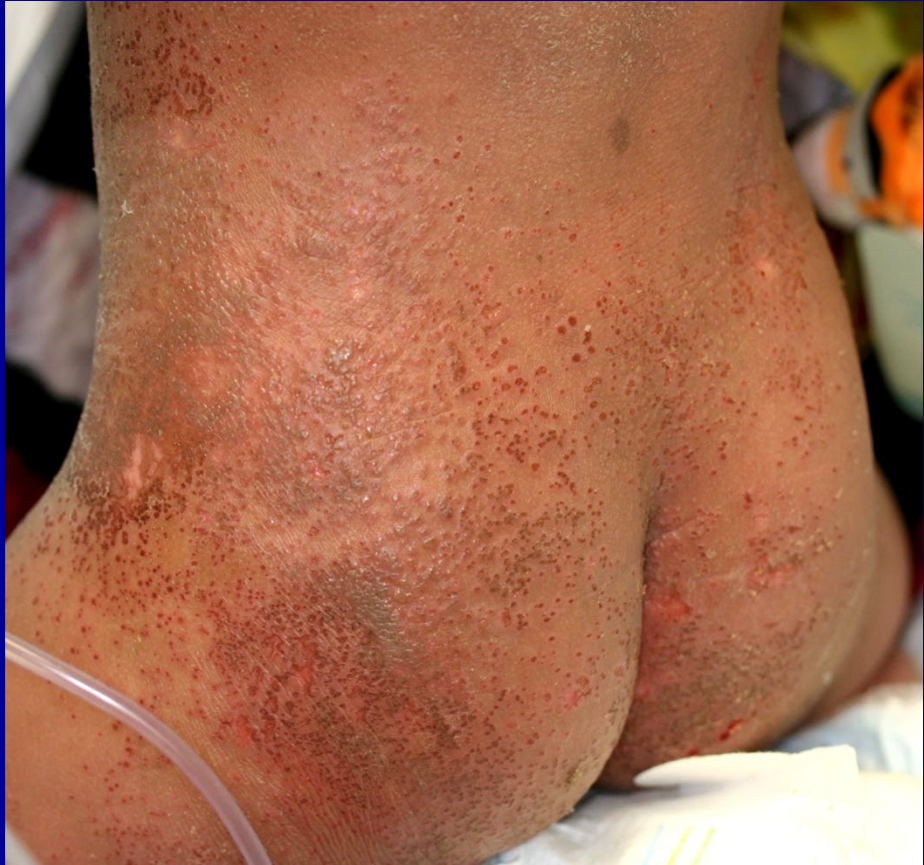- No financial conflicts of interest.

Learning Objectives

- Recognize features of several common skin conditions in children.
- Describe the features that support the correct diagnosis.
- Understand the recommended therapy for each condition.

Case #1

- 2 yr old female
- History of atopic dermatitis
- Flare worsening despite use of topical steroids
- Fever, malaise



What is the correct diagnosis?

- a) Eczema exacerbation
- b) Impetigo
- c) Eczema herpeticum
- d) Viral exanthem

Eczema Herpeticum

- HSV infection
- atopic dermatitis, other skin disease
- fever, malaise, widespread vesicles and erosions
- Complications: keratoconjunctivitis, bacterial superinfection, fluid loss

Eczema Herpeticum

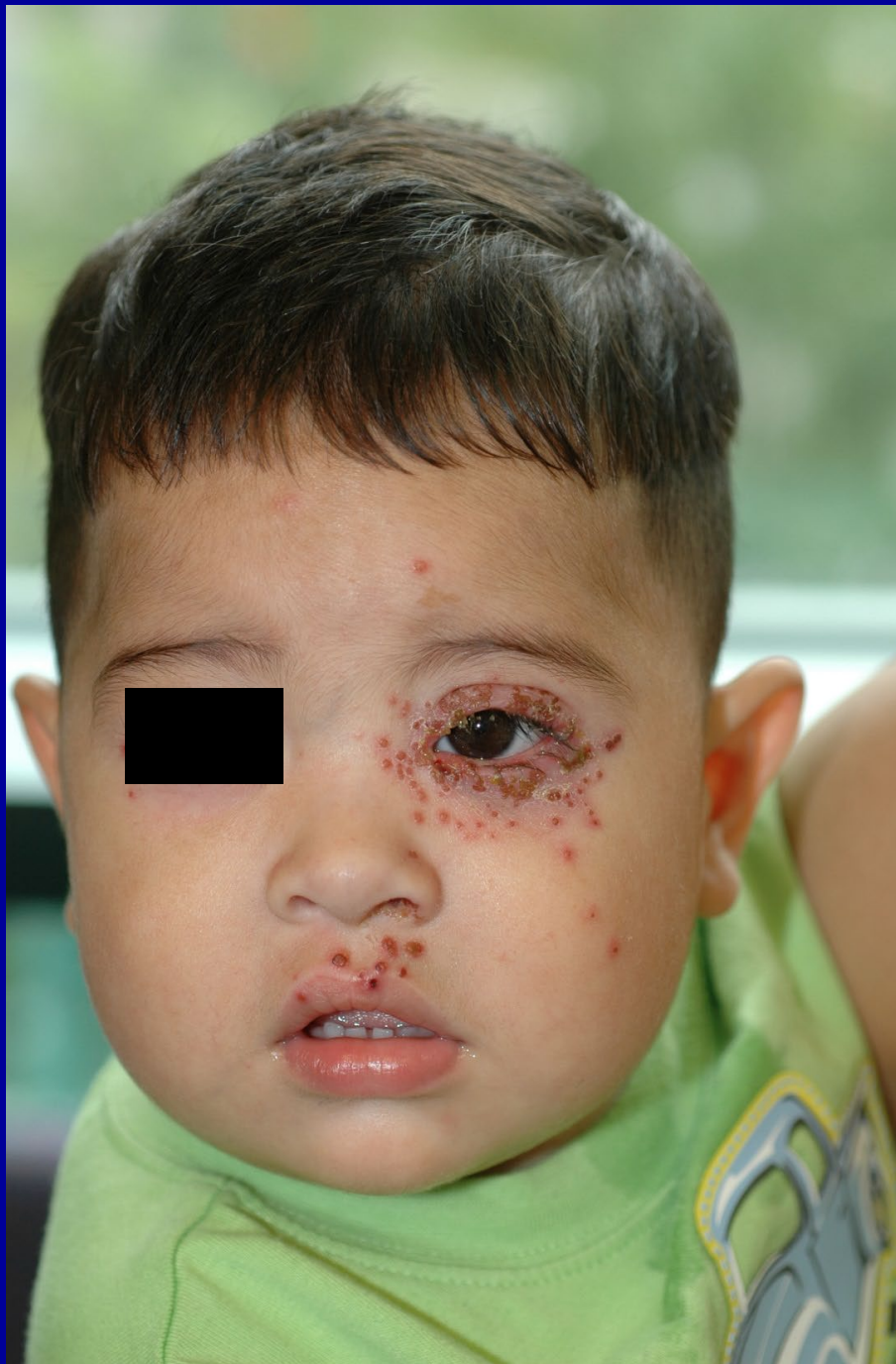- Diagnosis
 - History and physical appearance
 - HSV culture
 - Tzanck smear
 - DFA or PCR

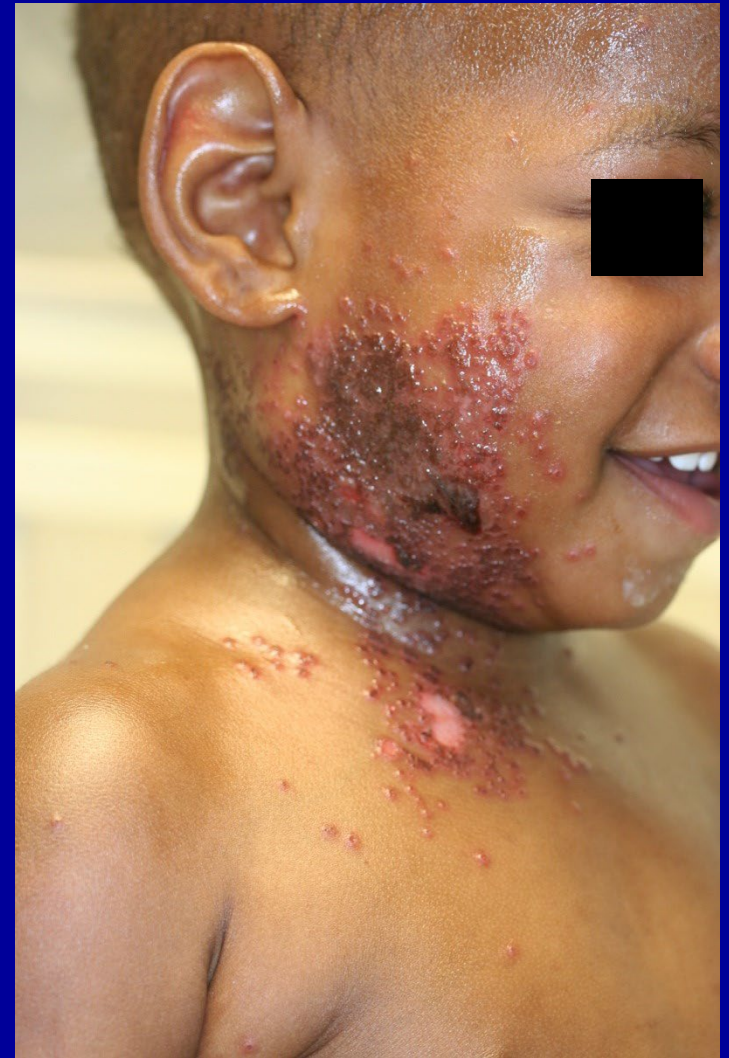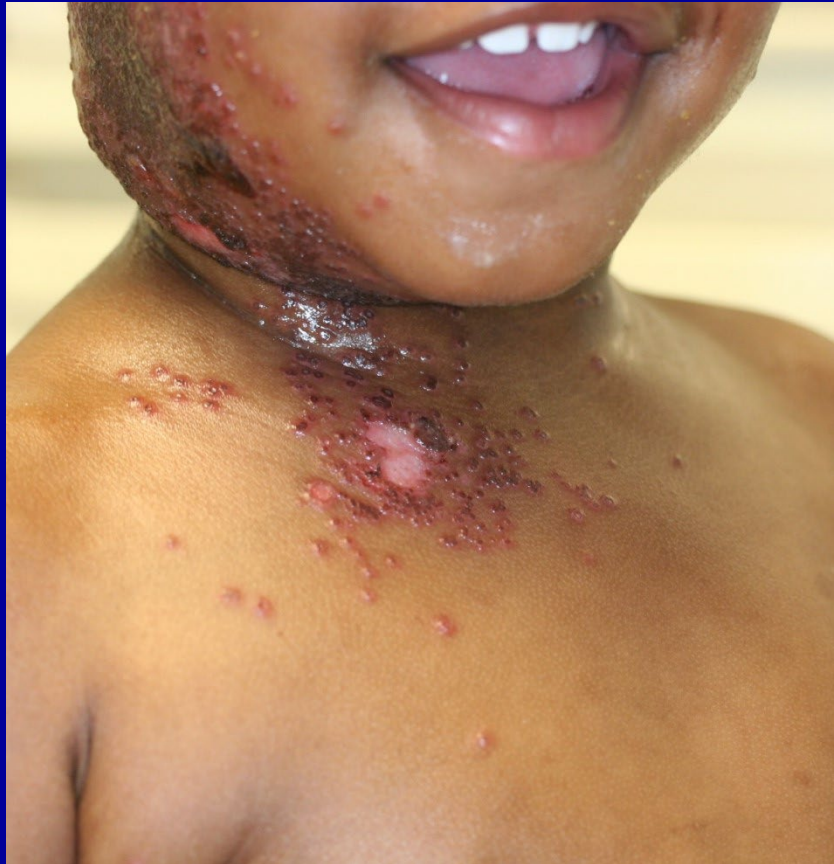Eczema Herpeticum

- Inpatient Management:
 - IV Acyclovir: 10 mg/kg/dose q 8 hr
 - antibiotic as indicated (bacterial cx!)
 - hydration, pain and fever control
- Outpatient management (po)
 - Acyclovir: 20 mg/kg/dose four times a day
 - Max dose = 800 mg four times a day

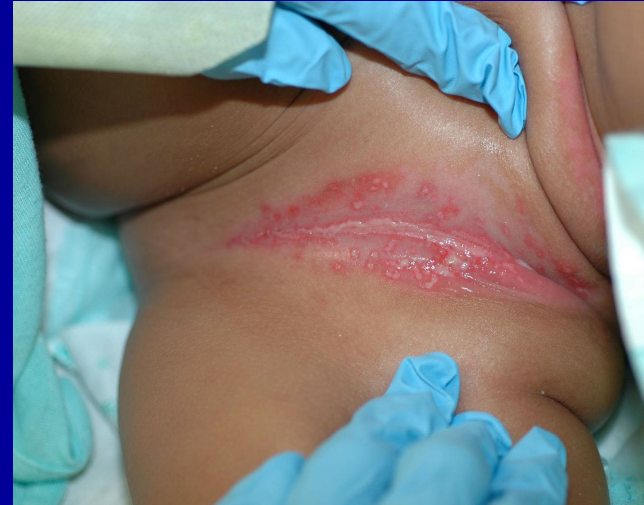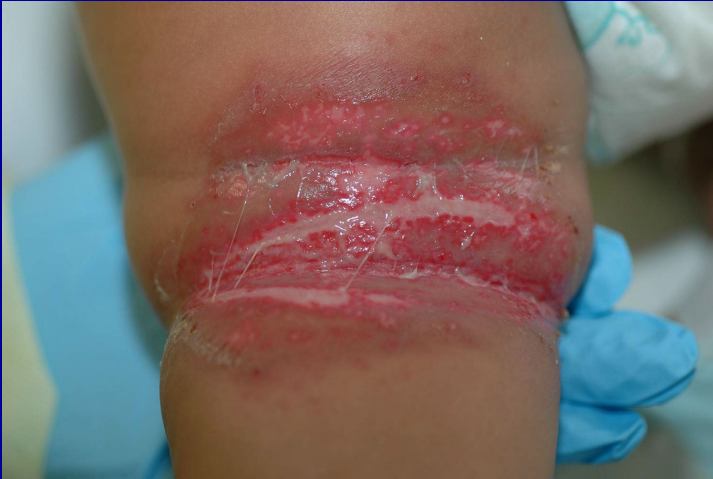Eczema Herpeticum

- Topical
 - No topical steroids!
 - Domeboro's soaks
 - 10 min each bid-tid
 - Bland emollients
- Lesions on eyelids
 - OPHTHO consult!

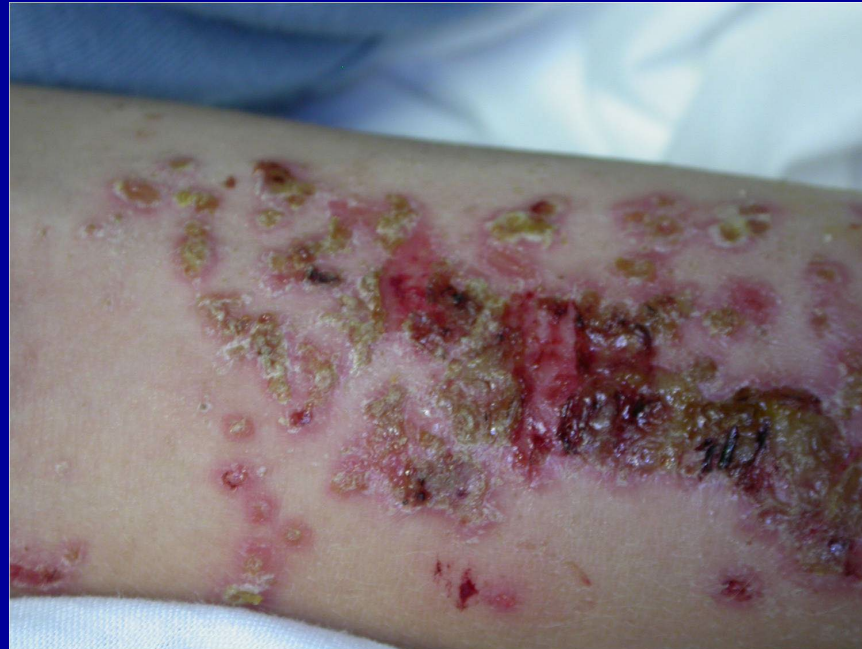


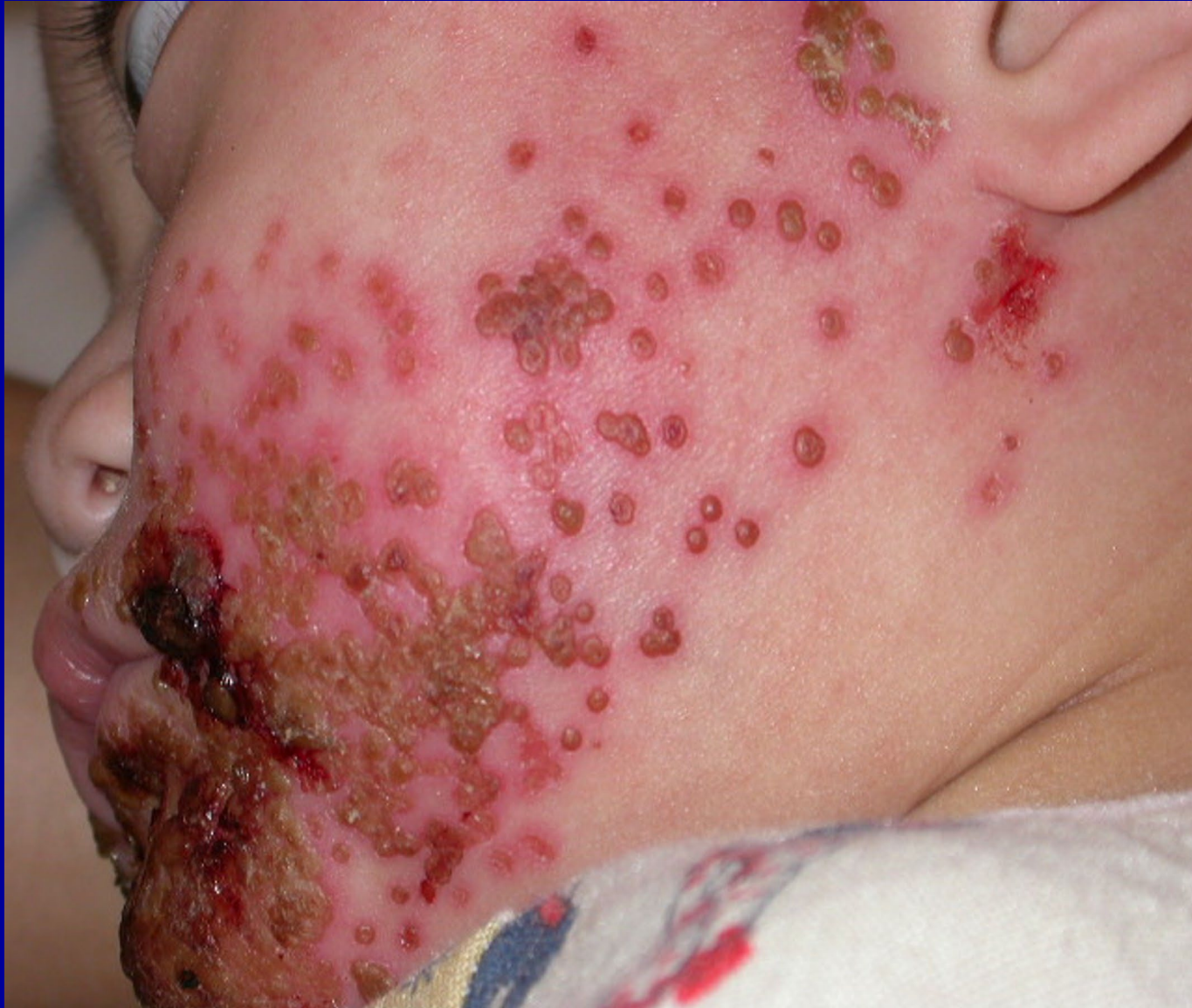
Cutaneous HSV



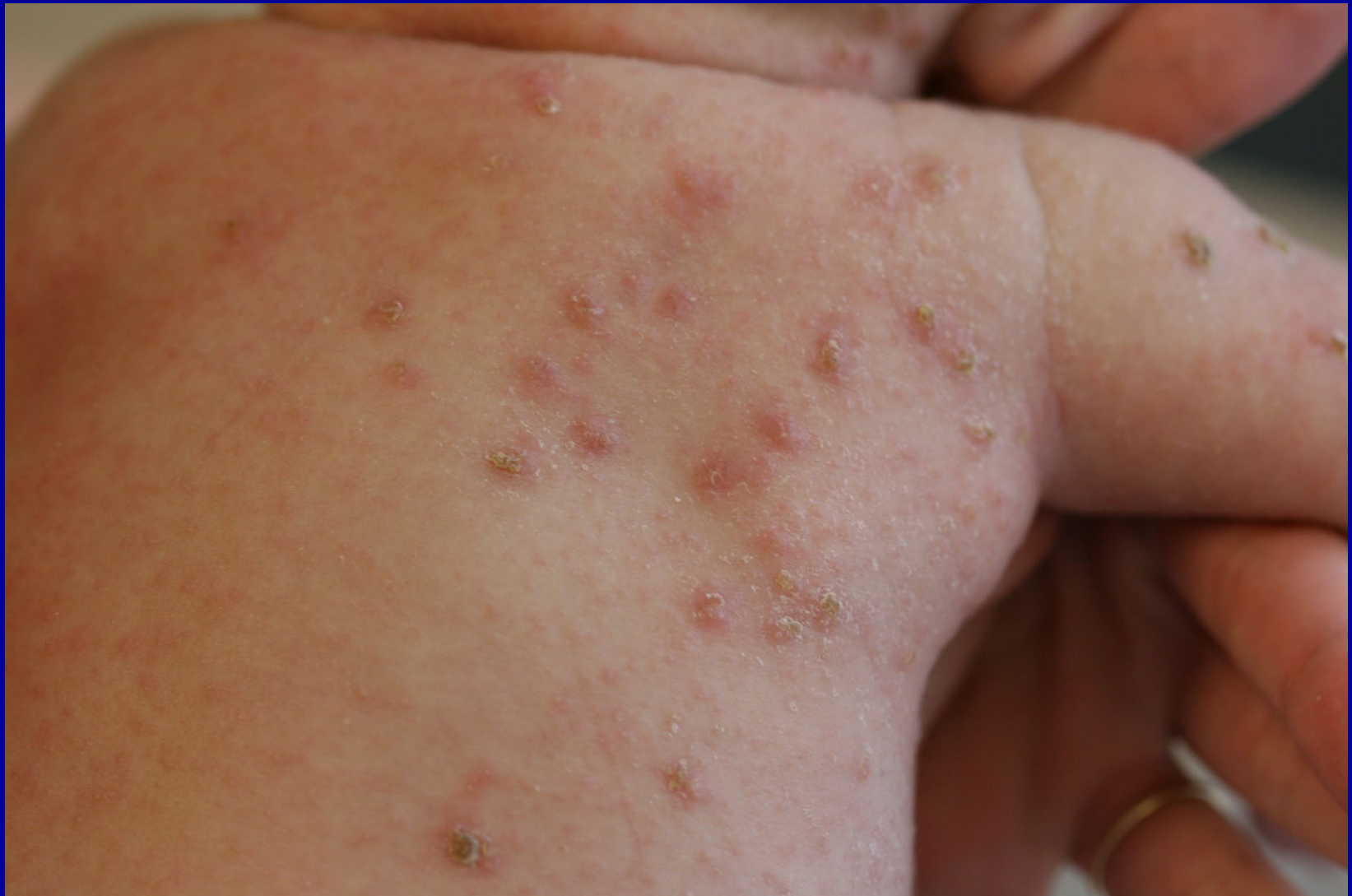Beware Impetigo!

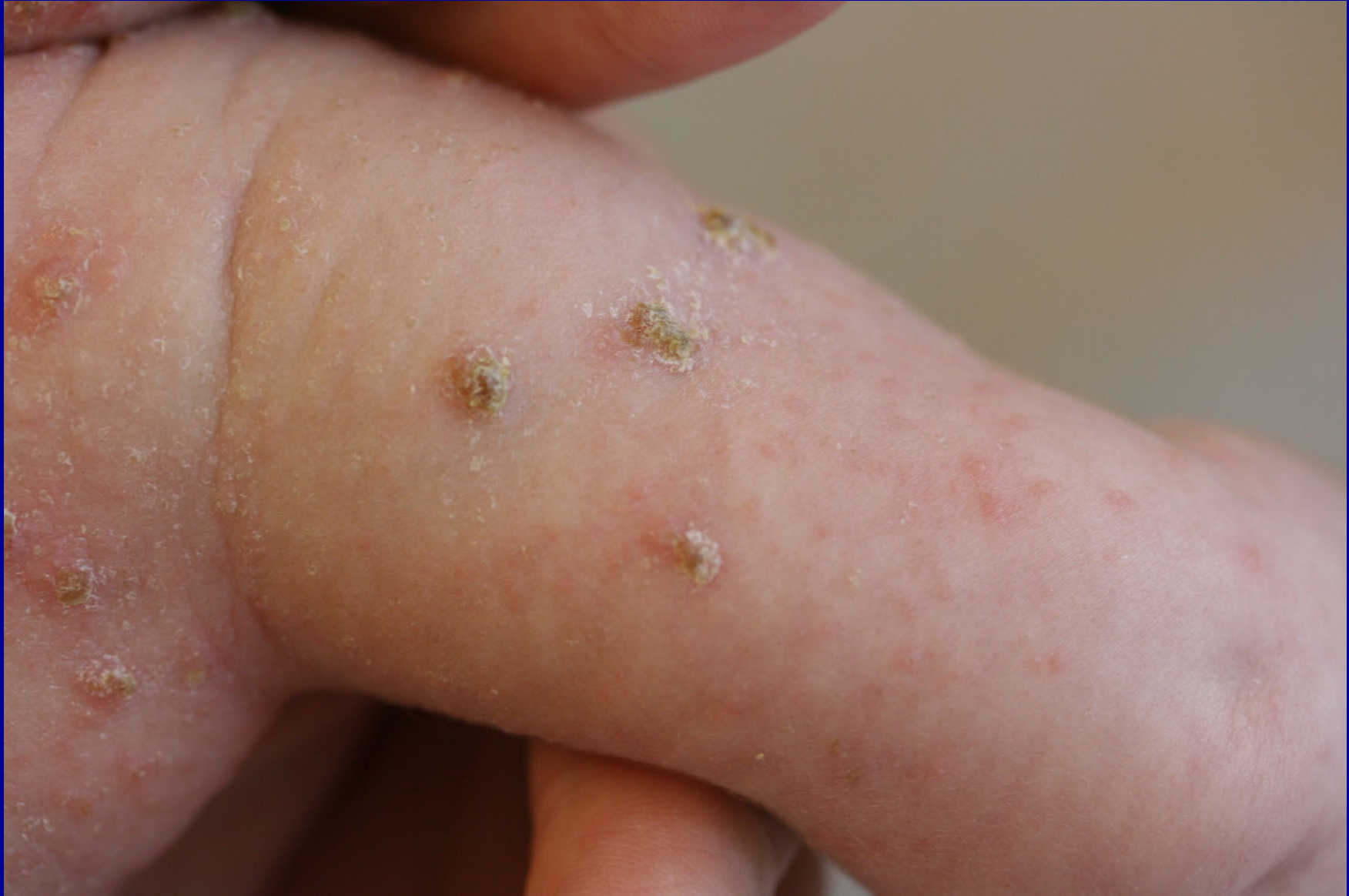



Case #2

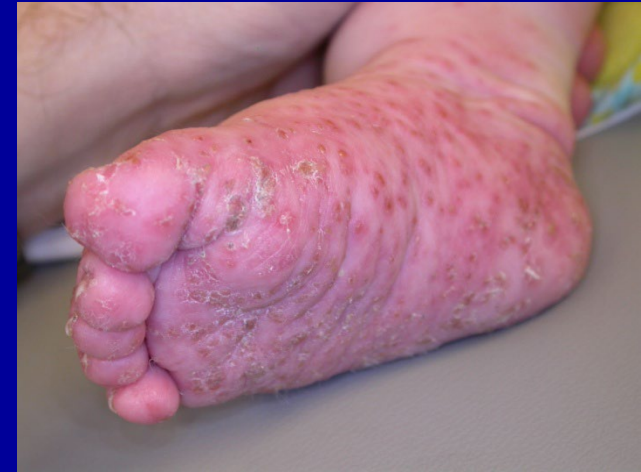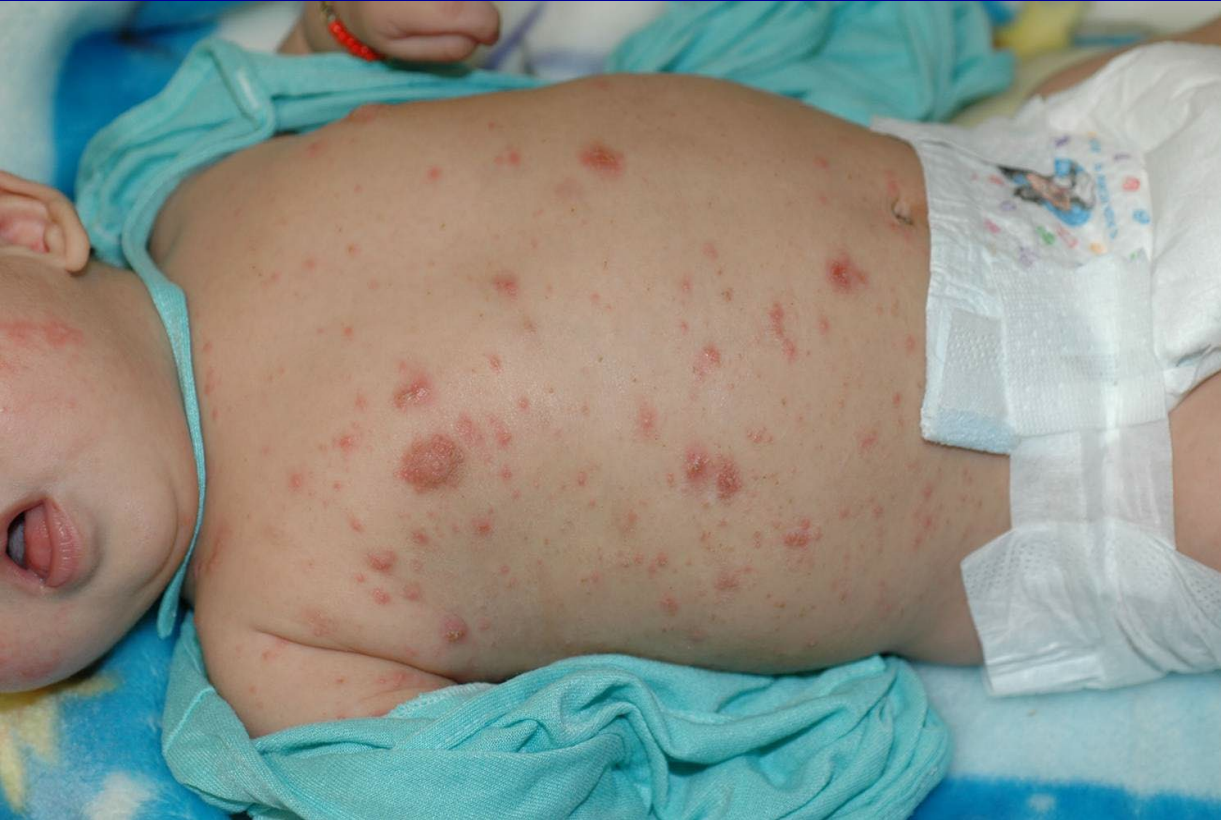- Previously healthy 2 mo old female
- 1 month of “worsening rash”
- treated with unknown oral antibiotic
- ? Mild itch
- No fever or other signs of illness
- No known sick contacts
- No contacts with rash



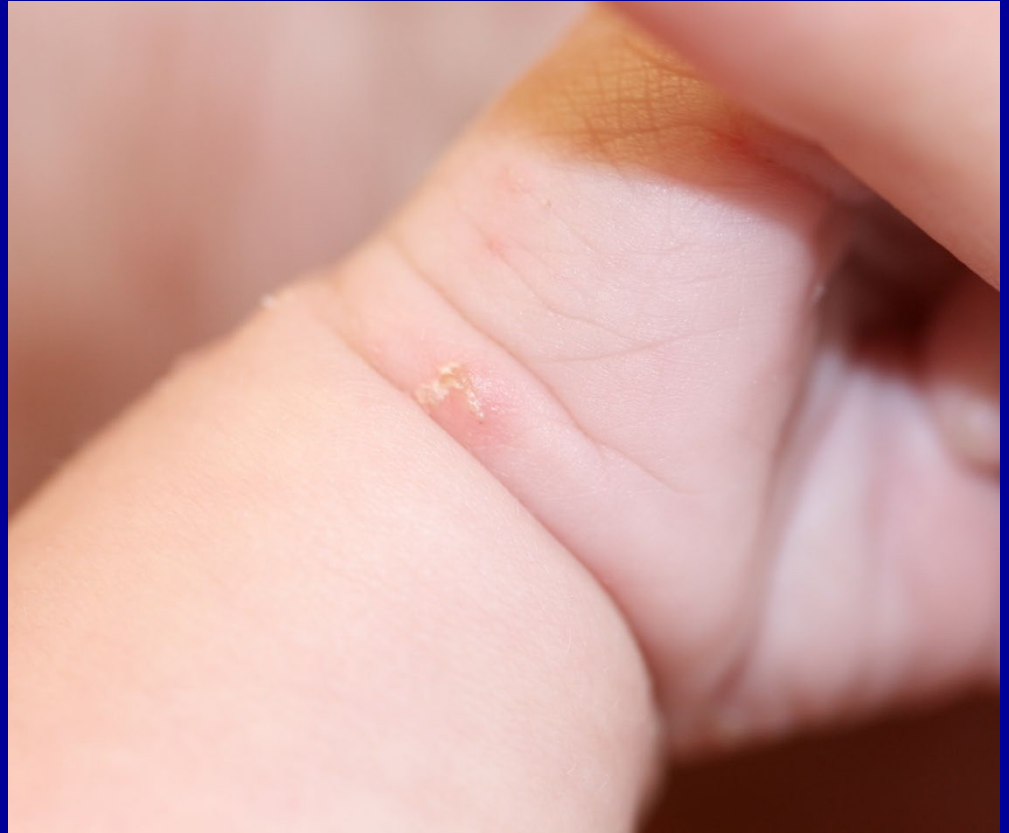
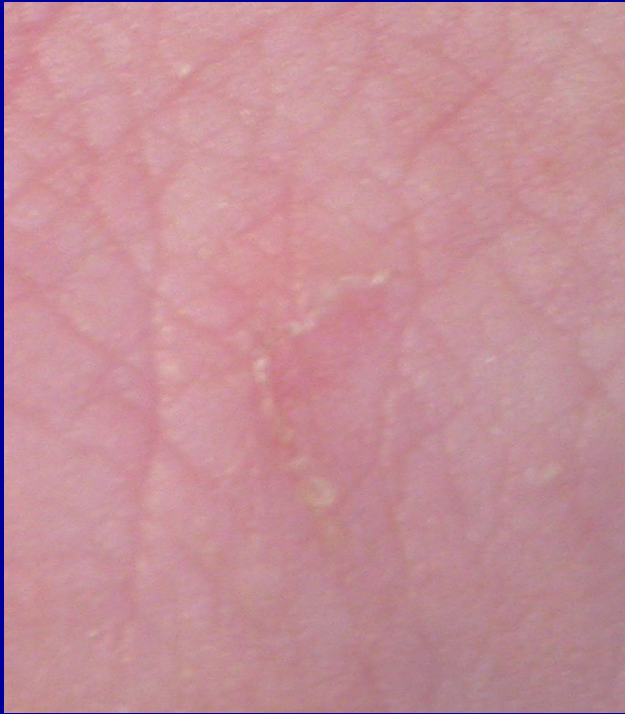
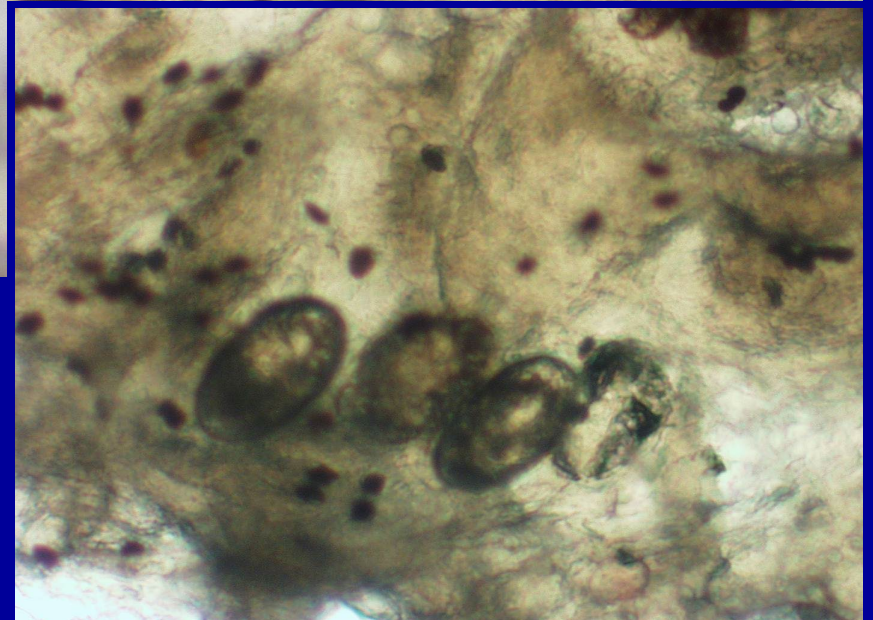
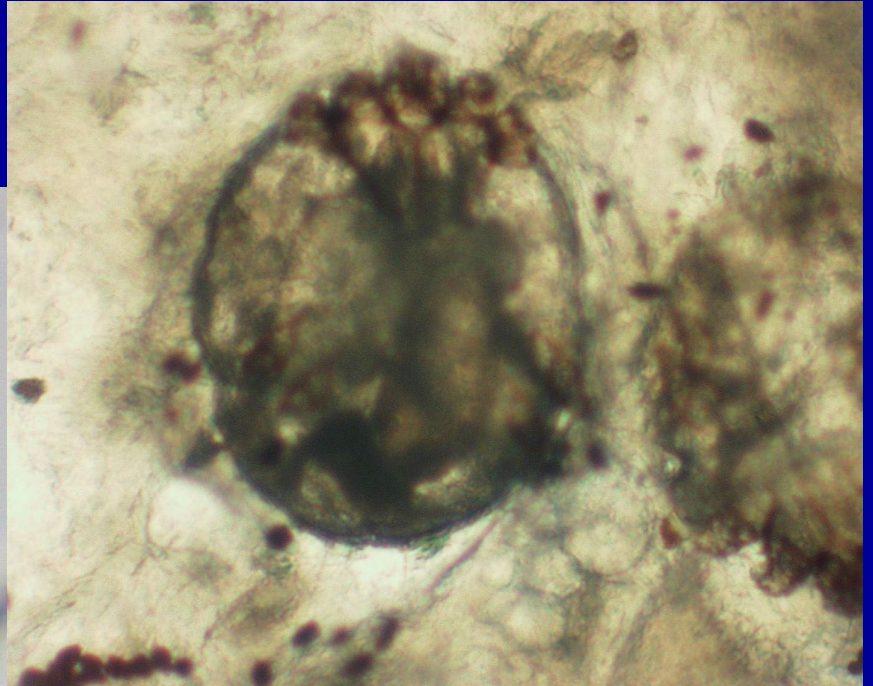

What is the correct diagnosis?

- a) Langerhans cell histiocytosis
- b) Leukemia cutis
- c) Viral exanthem
- d) Scabies



Burrows





Scabies

- Treatment (off label for <2 mos or pregnant/BF)
 - Permethrin cream 5% (Elimite)
 - Neck down for children/adults
 - **Include scalp/face for infants**
 - Leave overnight (8-14 hours)
 - Wash off in a.m.
 - Repeat treatment in one week
 - Launder clothing/bedding
 - Hot water, hot dryer
 - Large items: dry-clean or seal in bag for 1 week

Quarterman et al. Pediatr Dermatol 1994; 11(3):264-6.

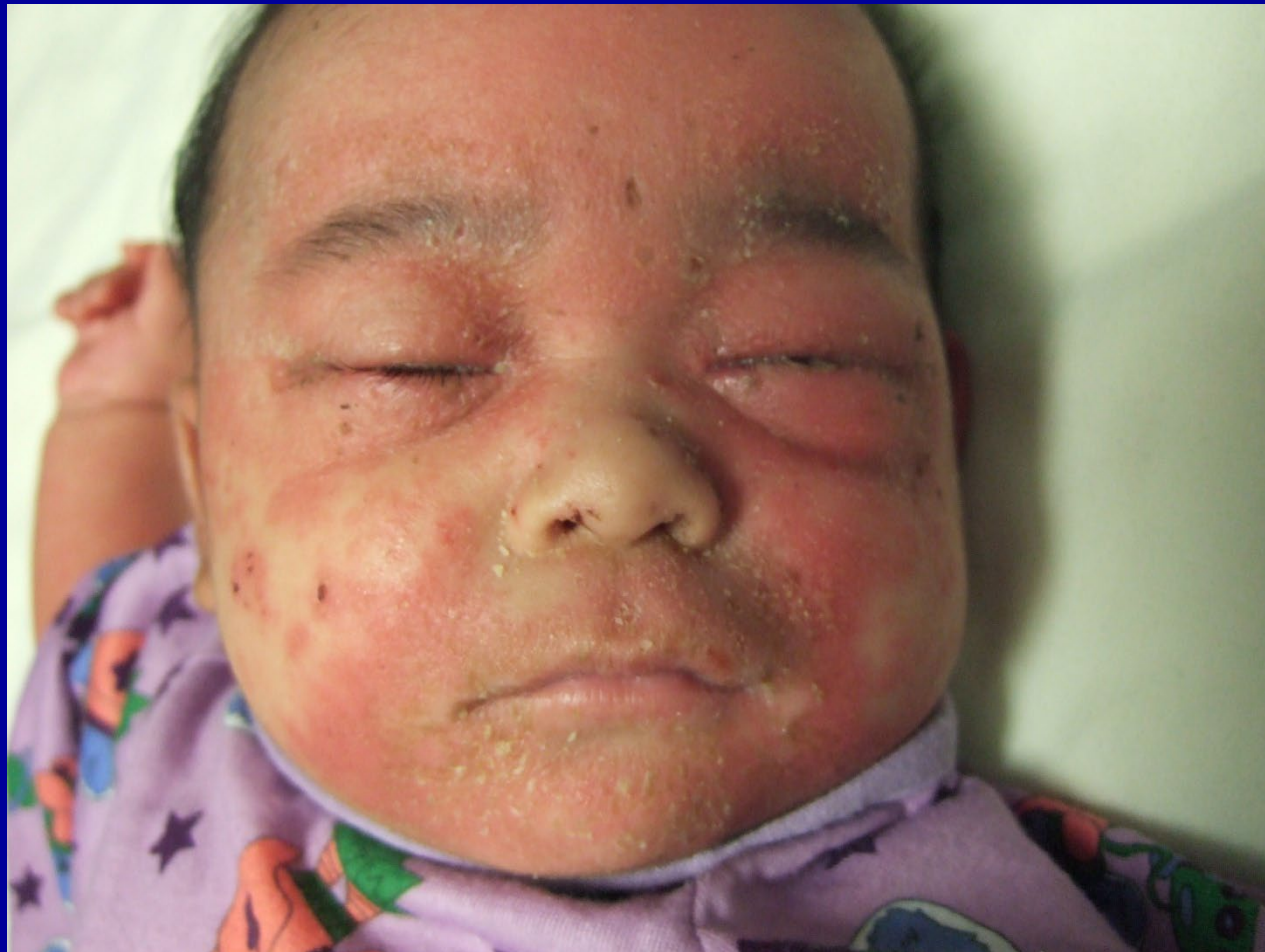Modi et al. Dermatol Online J 2018 May 15; 24(5).

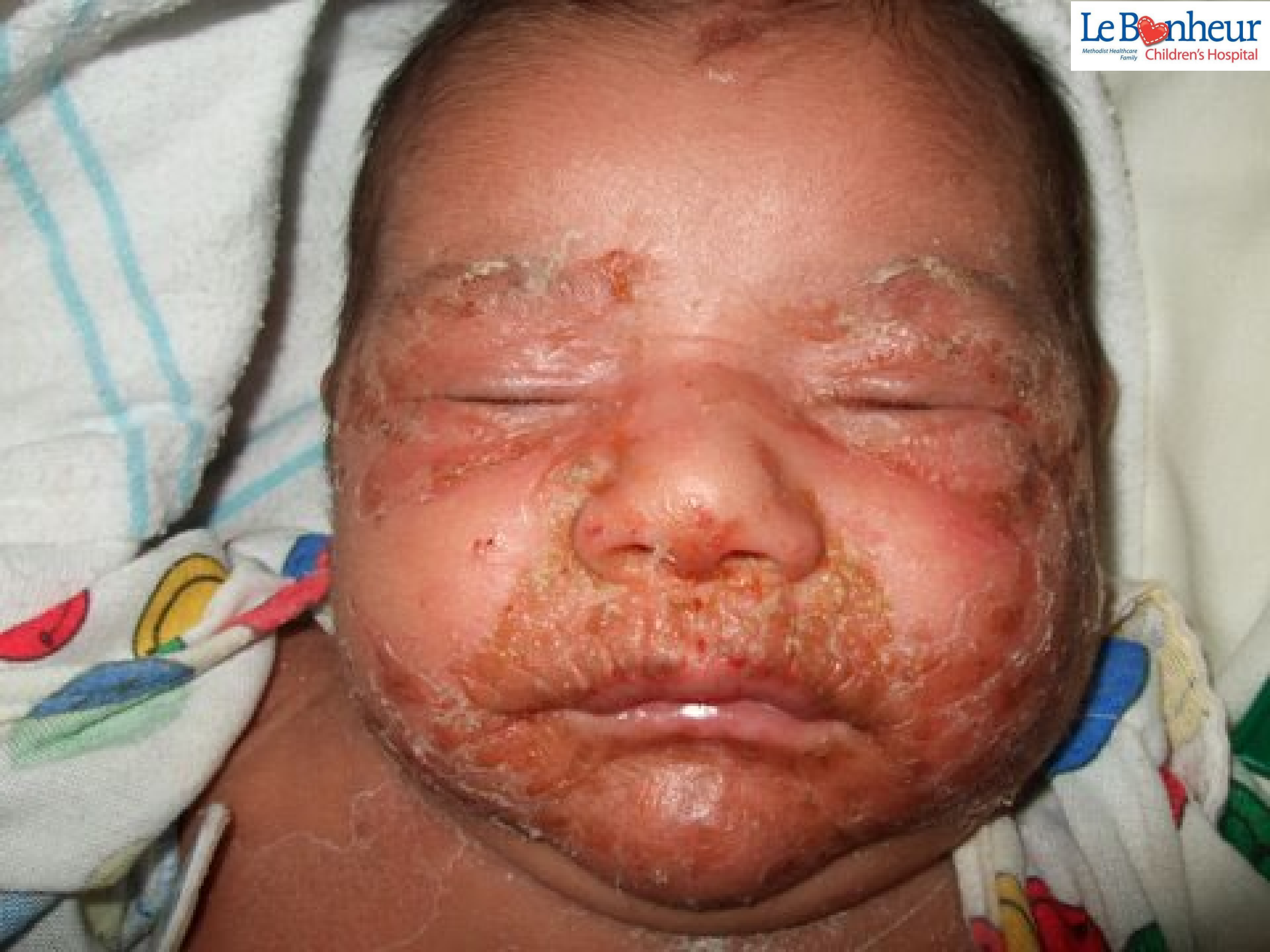Scabies

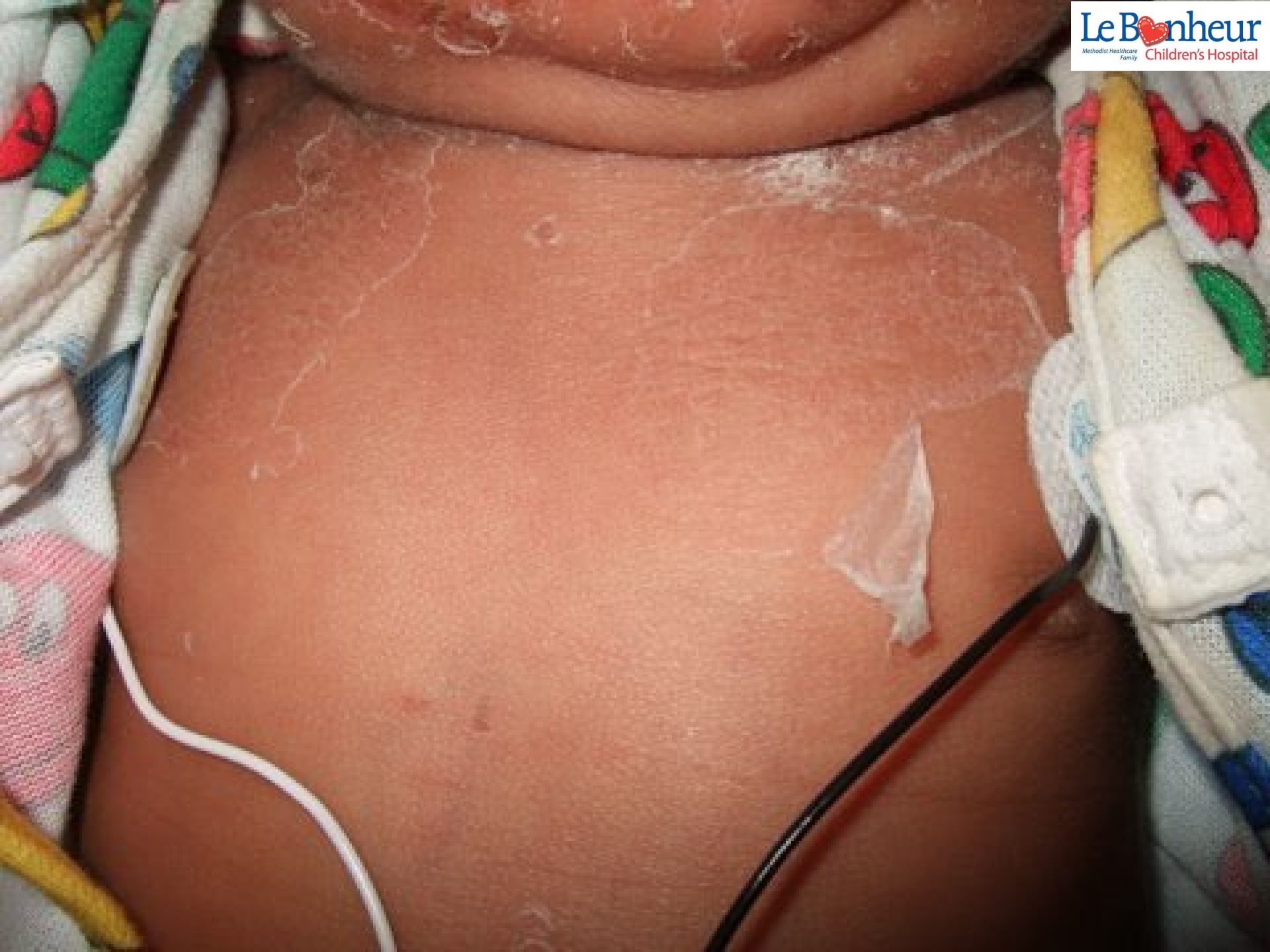- Education!
 - Treat all household members/close contacts at least once
 - Even if asymptomatic!
 - How to accomplish this?
 - Treat twice if itch/rash
 - Itching/rash may take several weeks to clear
 - Antihistamines
 - Mild topical steroid

Case #3

- 2 mo old FT healthy male
- Rhinorrhea/congestion
- Fussiness
- Red/tender skin
- Crusting around mouth
- Blisters and “peeling” of skin







Diagnosis?

- a) Impetigo
- b) Stevens Johnson Syndrome (SJS)
- c) Staph Scalded Skin Syndrome (SSSS)
- d) Toxic Epidermolysis Necrosis (TEN)

Staph Scalded Skin Syndrome (SSSS)

- Staph aureus
 - Exfoliative toxin
 - Cleavage at superficial epidermis
 - Stratum granulosum
 - Pathogenesis:
 - Target Desmoglein 1
 - Why neonates and young kids?
 - Lack of antitoxin antibodies
 - Low renal excretion of toxin

SSSS

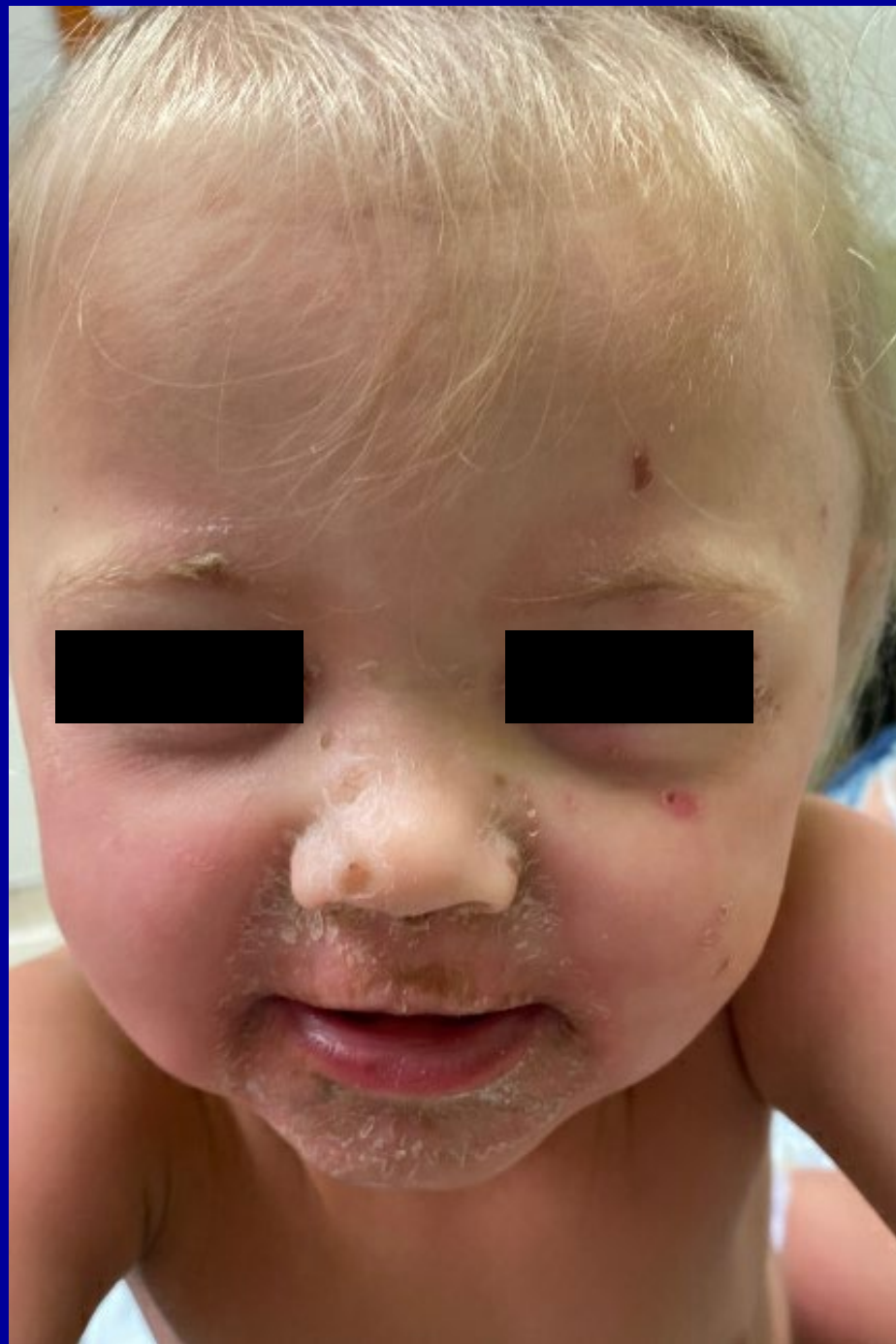- Source?
 - Eyes, nares, perioral, perineum, umbilicus
- Clinical
 - Fever, malaise, irritability
 - Tender erythema, fragile bullae, erythematous erosions
 - Flexural creases
 - + Nikolsky sign

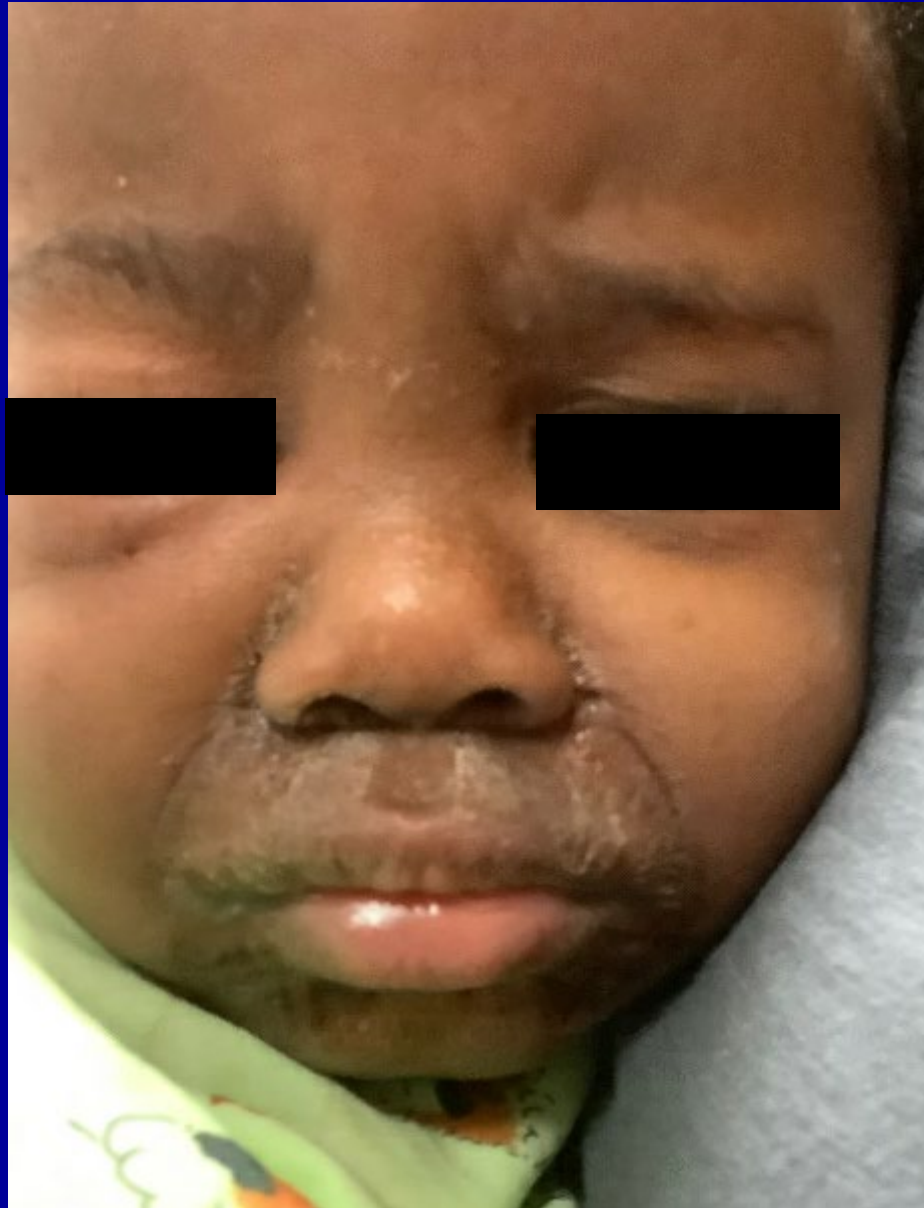SSSS

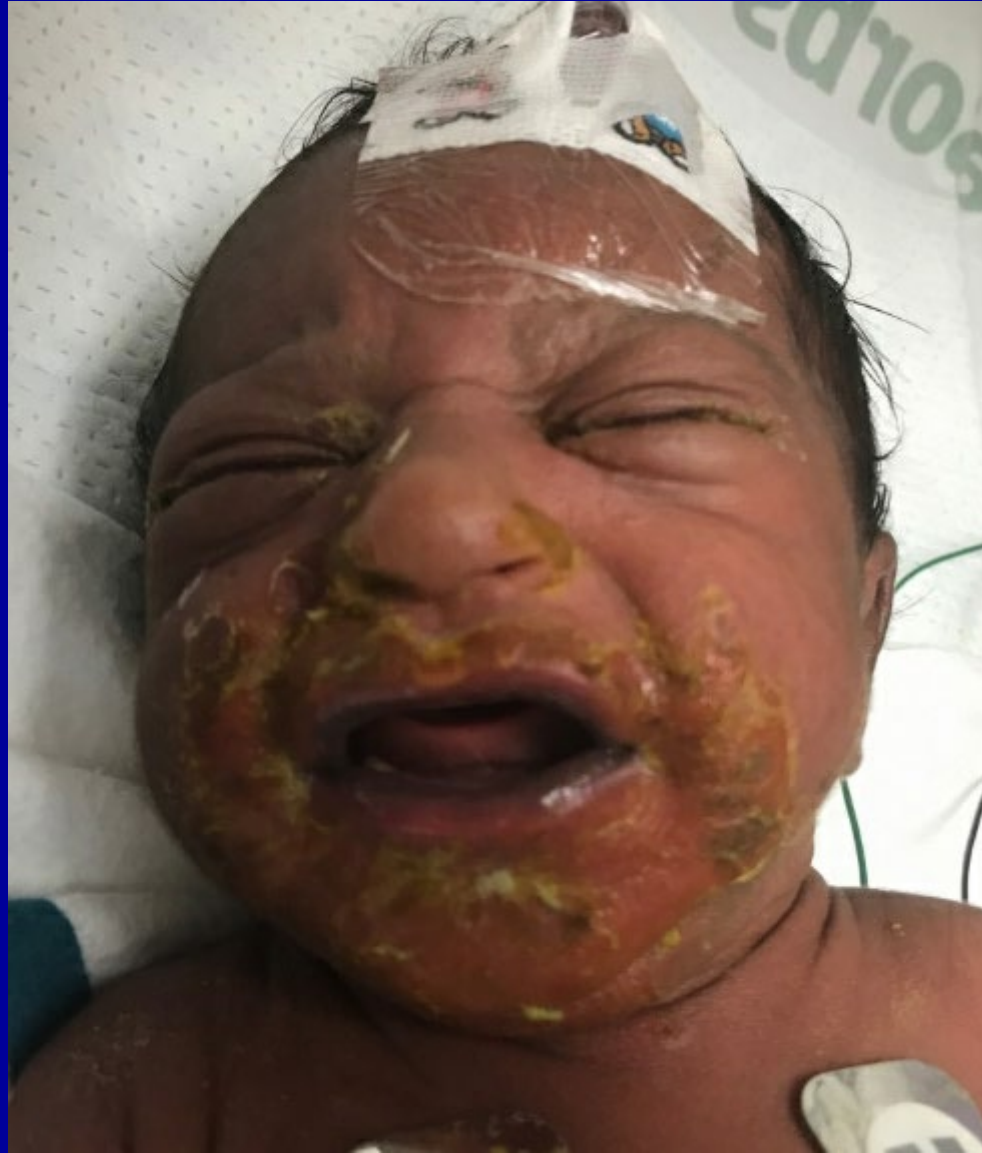- Diagnosis
 - Clinical
 - Culture? Where?
- TEN?
 - Mucosal involvement
 - Sub epidermal split

SSSS

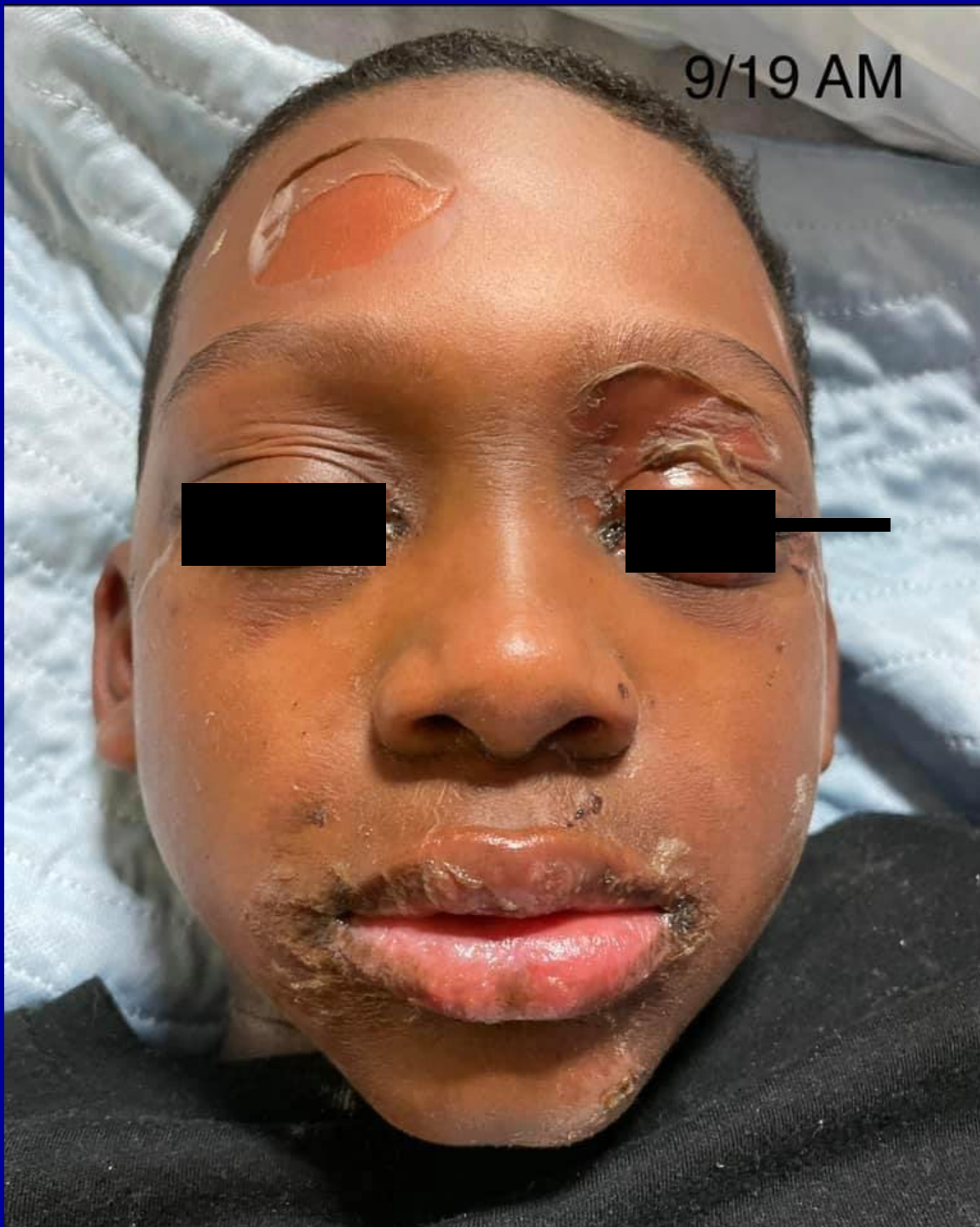- Treatment
 - Clindamycin
 - PCNase resistant PCN
 - Cephalosporin
 - MRSA: vancomycin
- Supportive care
 - IVF's
 - Pain control
 - Wound care
 - Gentle cleansing, soaks, emollient



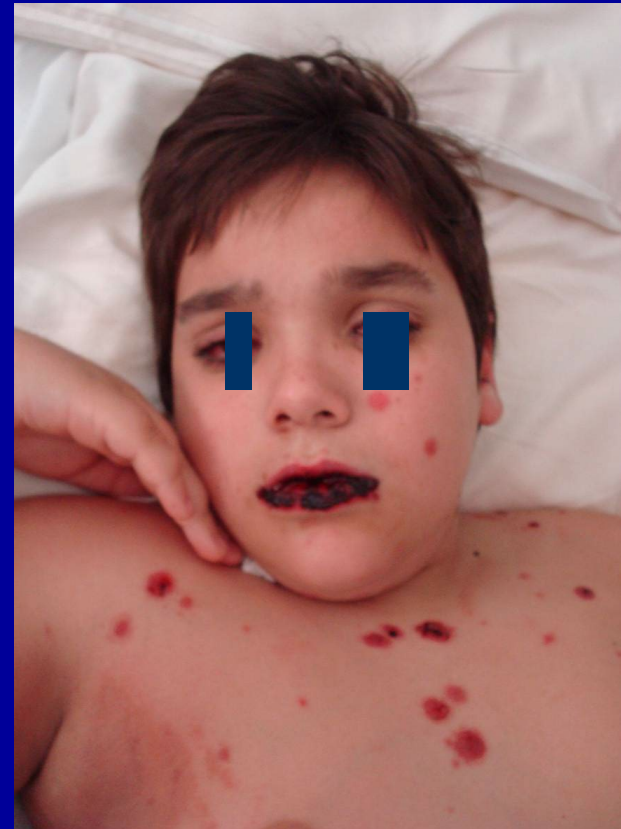
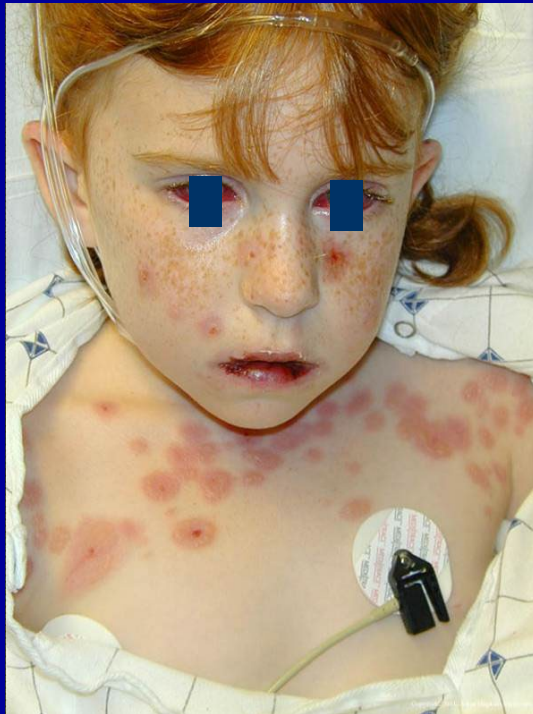


9/19 AM

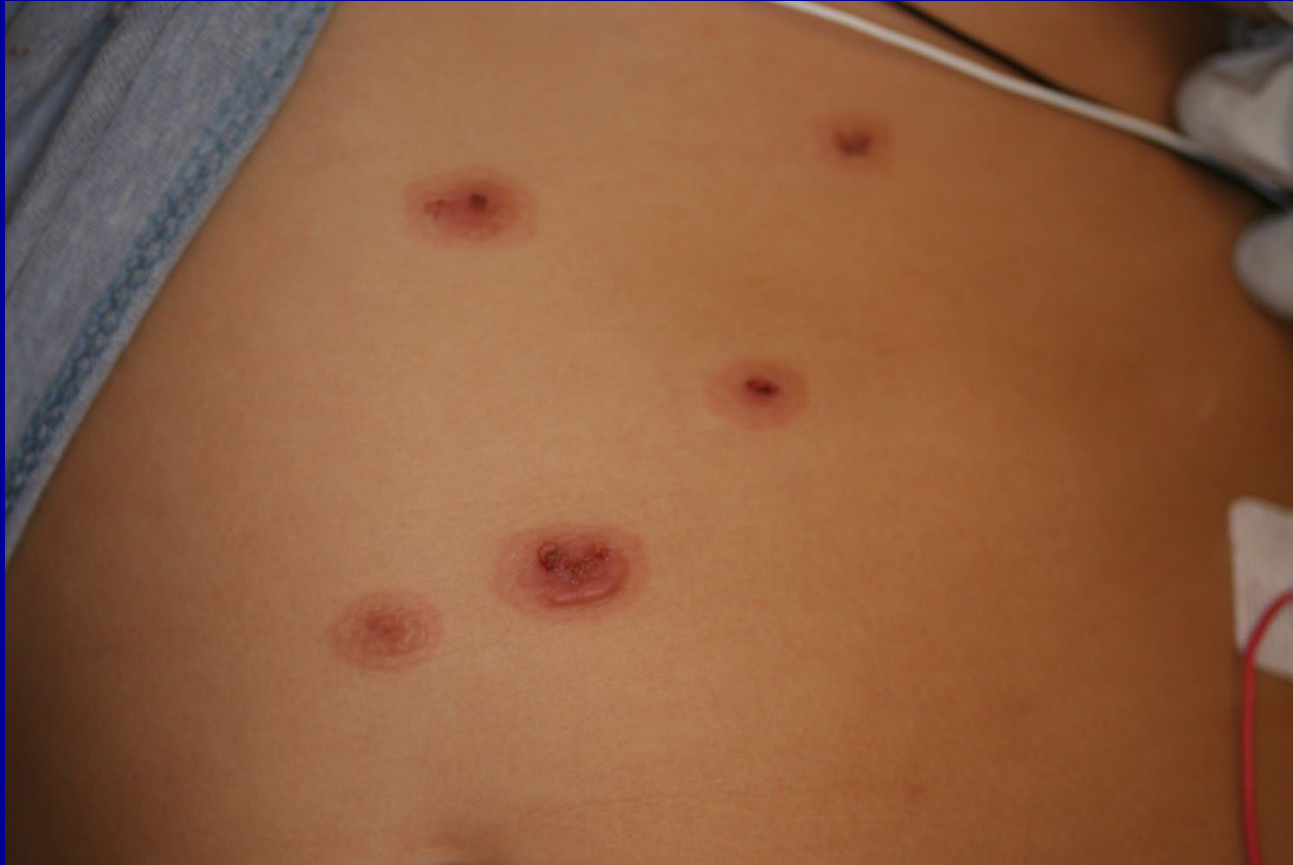

Stevens Johnson Syndrome (SJS)



SJS

- Fever, malaise, skin/mucous membrane lesions
- Prodrome 1-14 days
- Skin lesions
 - Often EM like
 - Vesicles, bullae, epidermal sloughing



SJS

- <10% TBSA
- Two or more mucous membranes
 - Eyes
 - Mouth/esophagus
 - Trachea
 - Genital/urethral/peri-anal skin

SJS

- Pathogenesis
 - Immune activation
 - Keratinocyte death

SJS

- Etiology
 - Up to 90% drug-related
 - Over 200 drugs
 - Sulfa
 - Anticonvulsants
 - NSAID's
 - Allopurinol
 - Penicillin
 - Typically within 1-4 weeks
 - 10% infection

SJS

- Diagnosis
 - Clinical
- Treatment
 - Supportive
 - Multi disciplinary
 - Wound care
 - Fluids/electrolytes
 - Nutrition
 - Pain control
 - Treat secondary infection

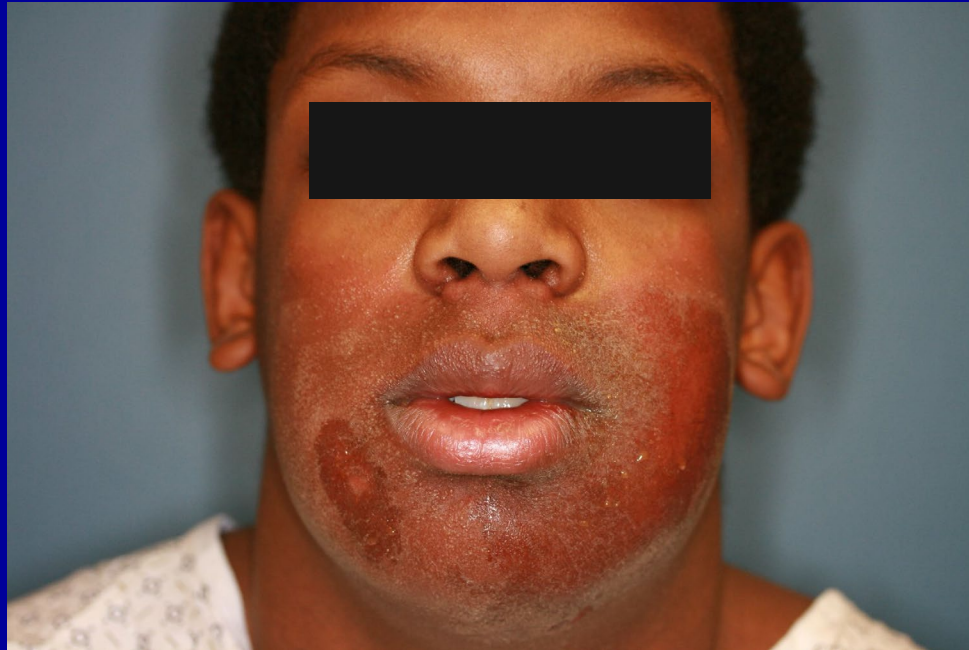SJS

- Treatment
 - Cessation of drug!
 - Controversial
 - IVIG, steroids, cyclosporine, etanercept, other
- Recovery
 - Weeks

Belver MT et al. Allergol Immunopathol. 2016 Jan-Feb; 44(1):83-95.
Kirchhof MG et al. J Am Acad Dermatol. 2014 Nov; 71(5):941-947.

Case #4

- Previously healthy 14 yr old male
- Hospitalized for three days for “facial cellulitis”
- After d/c, rash/swelling of face recurred
- Returned to the ED and was referred to dermatology



Diagnosis?

- a) Cellulitis
- b) Eczema herpeticum
- c) Allergic contact dermatitis
- d) Pustular psoriasis

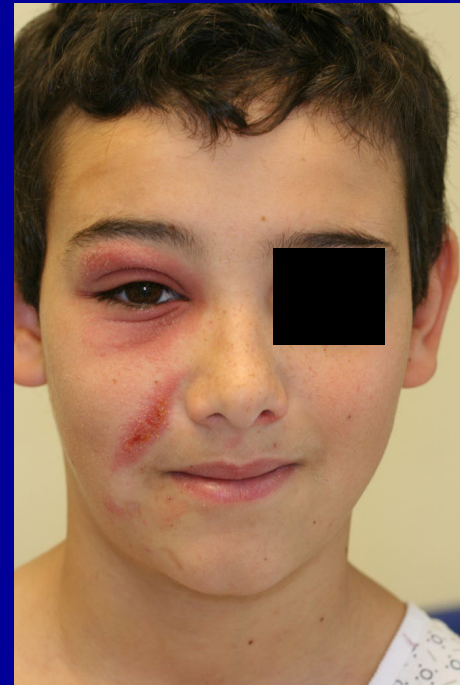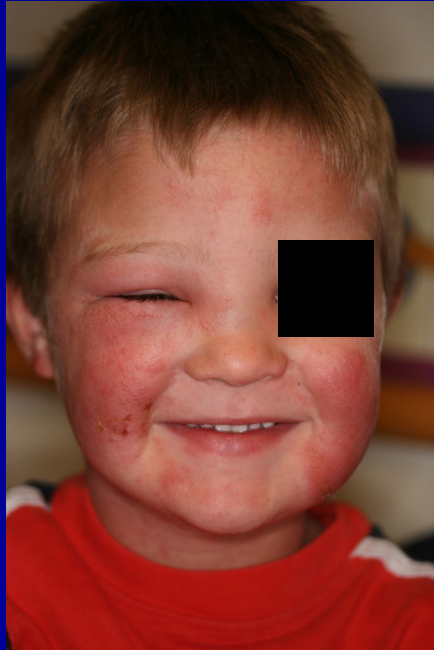ACD

- Acute lesions
 - Erythema, edema, papules, vesicles/bullae, oozing, sharply defined
 - Intense pruritus
 - Multiple areas
 - Secondary bacterial infection possible
 - More purulent
 - More tender

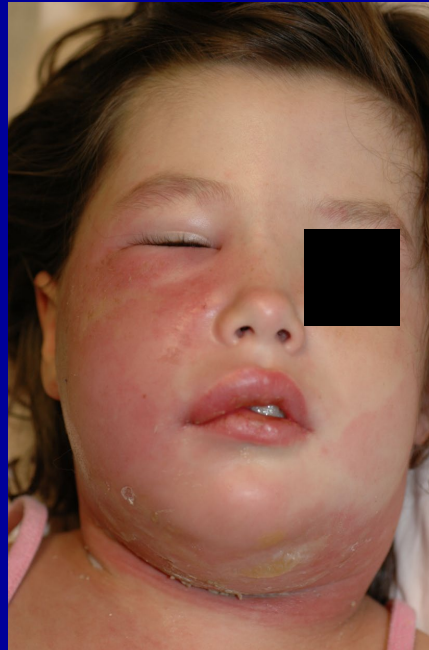Bacterial Cellulitis

- Factors that may be helpful
 - Tenderness/pain prominent
 - Borders less sharply defined
 - Malaise/fever
 - Elevated wbc
 - Child looks sicker
 - Especially if facial

ACD

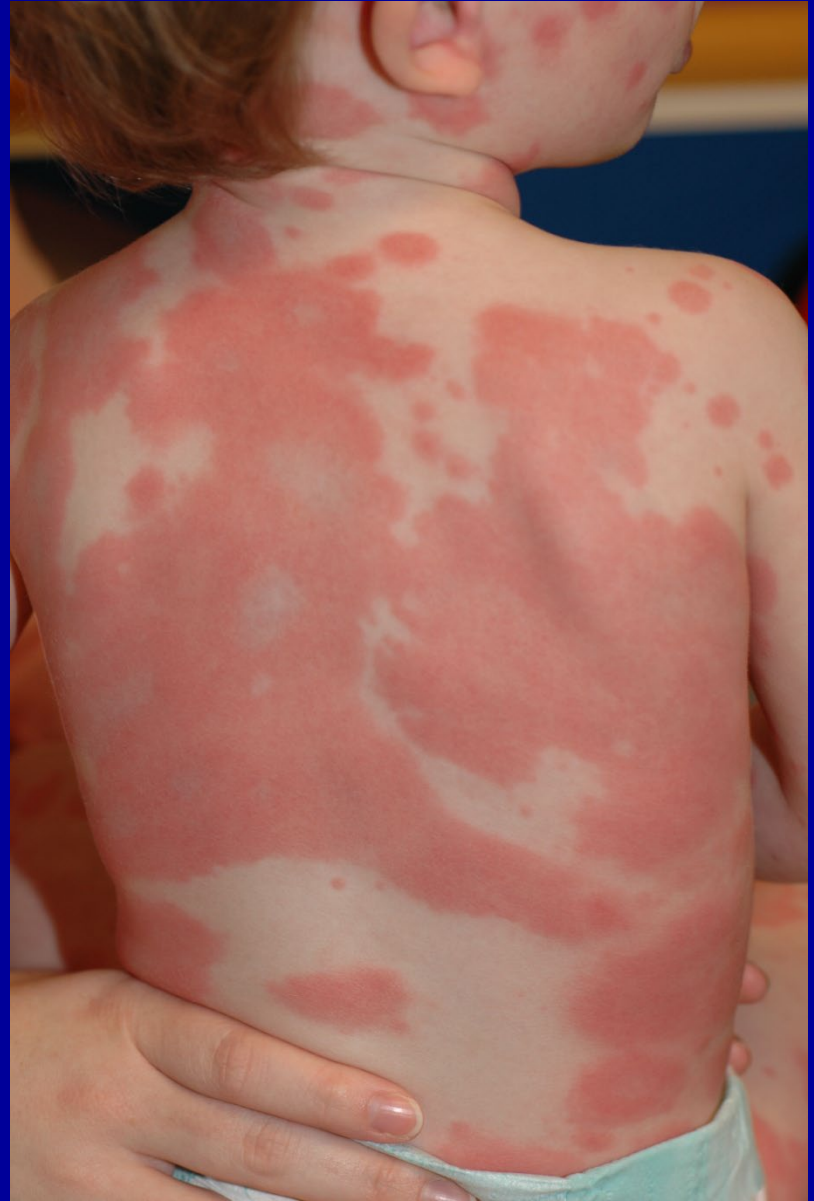
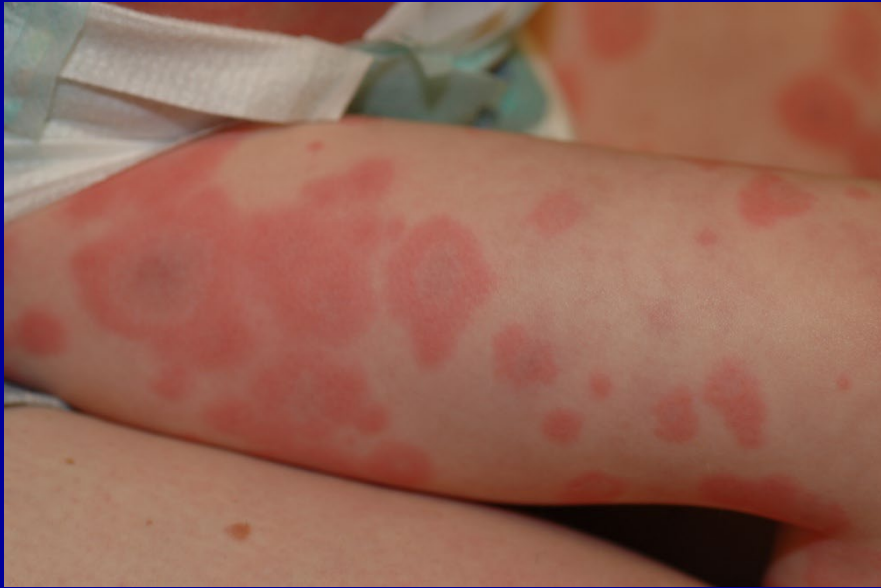
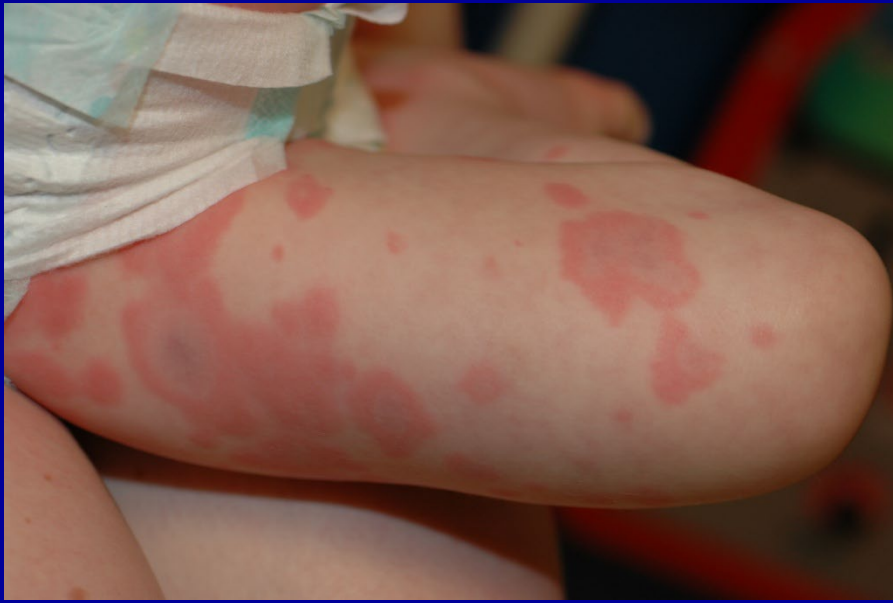Facial Cellulitis



Case #5

- Previously healthy 14 mo old female
- 2 day history of fever, URI
- Seen by PMD yesterday and started on Augmentin for OM



What is your diagnosis?

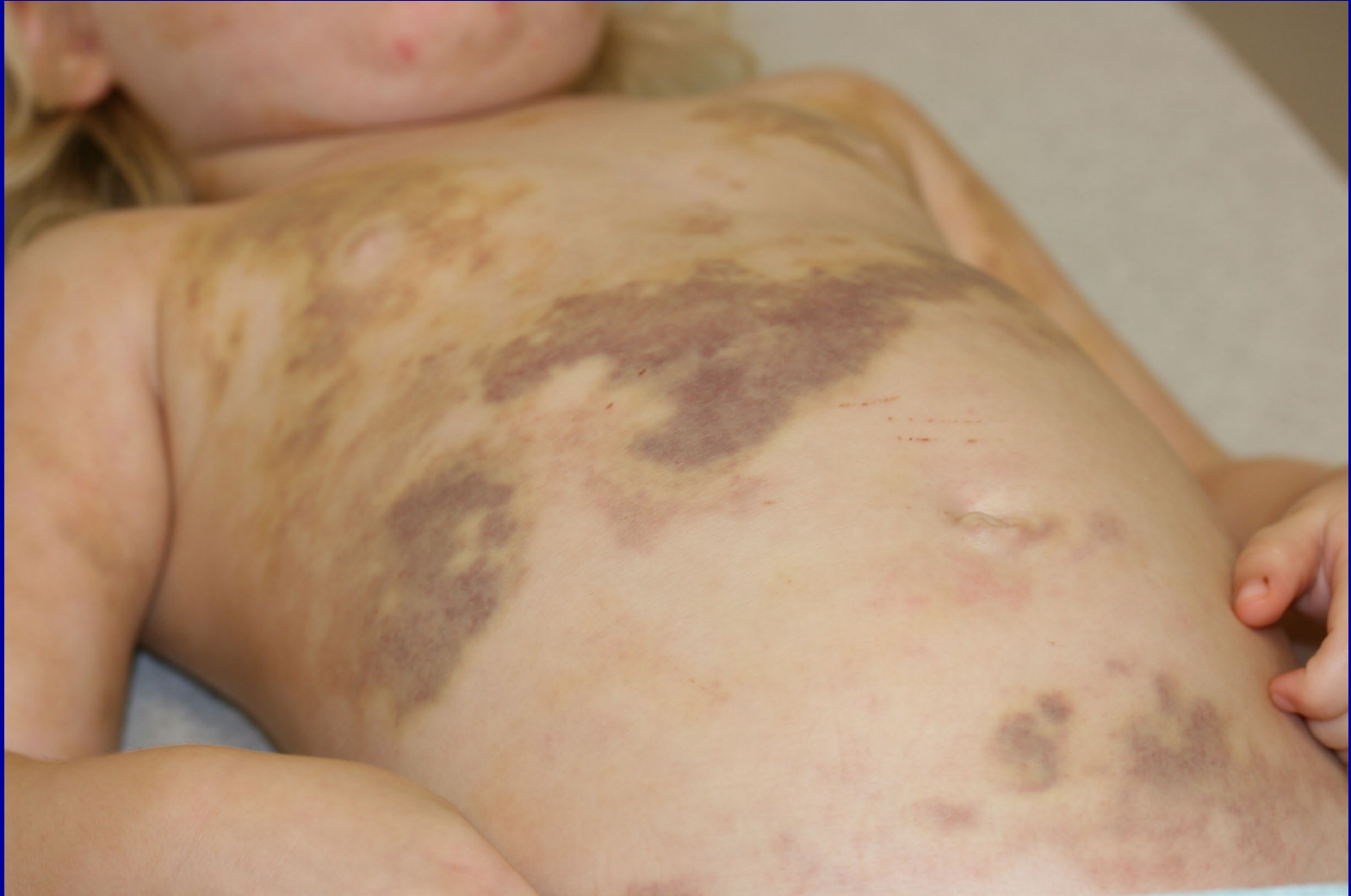- a) Erythema multiforme
- b) Stevens Johnson syndrome
- c) Urticaria
- d) “Serum sickness”

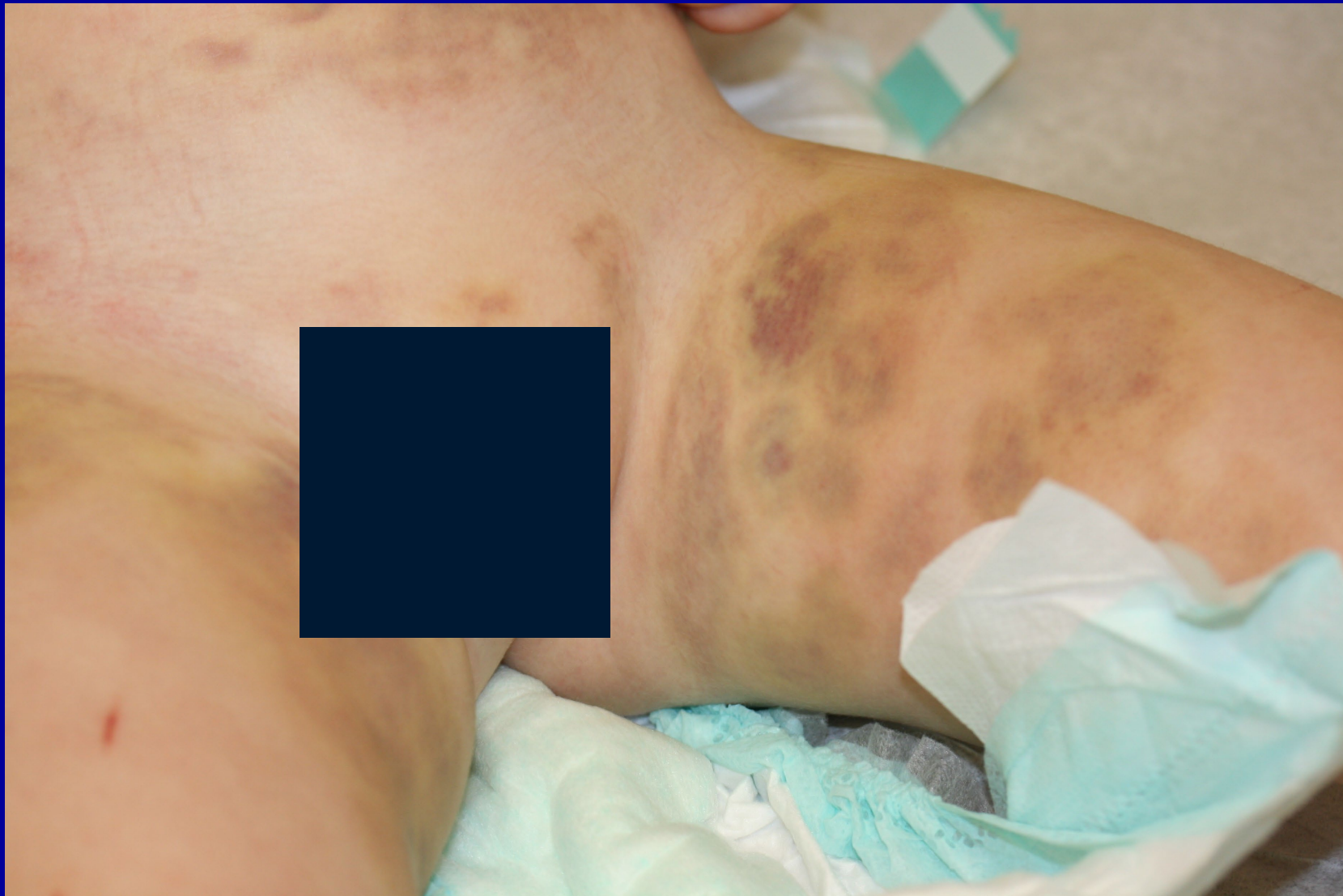Urticaria

- Transient, erythematous wheals
- Small, localized vs. large, generalized areas
- SQ involvement- giant urticaria, acute annular urticaria
 - Swelling of face, distal extremities
 - Acrocyanosis
 - Central duskiness
 - “urticaria multiforme”

Urticaria

- Individual lesions rarely persist >12-24 hours
 - >24-36 hours, suspect other etiology
 - Urticarial vasculitis
- Usually pruritic





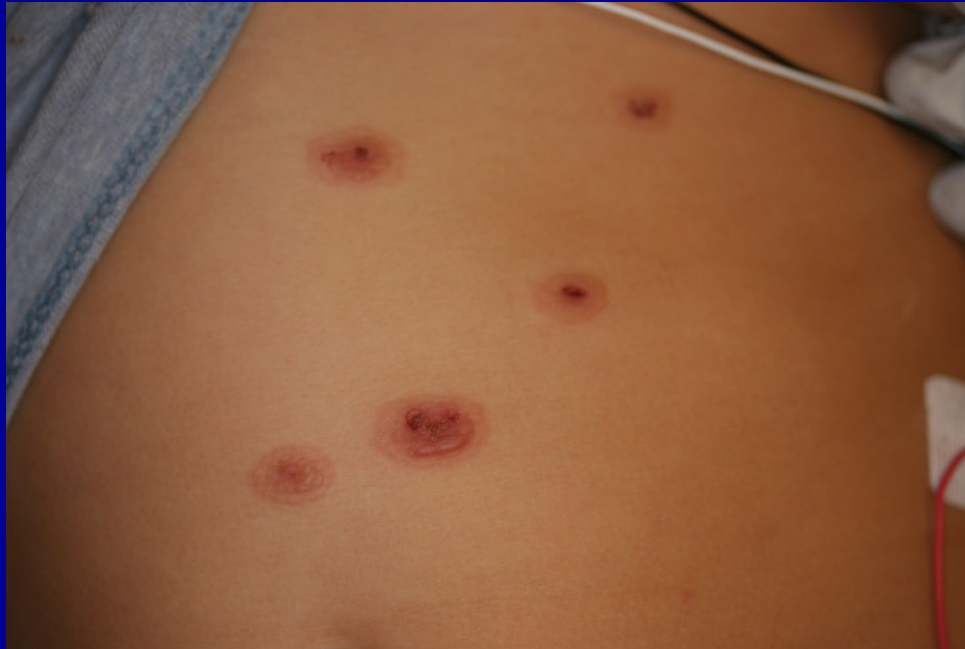Urticaria

- Etiology
 - Acute <6 weeks
 - Children, viral infection
 - Other infection(s)
 - Foods
 - 10% drug-related
 - » Penicillins
 - Chronic >6 weeks
 - Less common in children
 - 80% idiopathic

Urticaria

- Treatment
 - Eliminate trigger
 - Symptomatic
 - Antihistamines
 - sedating/non-sedating H1 and H2
 - Other
 - Cool baths, cool compresses
 - Cooling lotions (Sarna®, Eucerin® Calming)
 - ? Steroids

Erythema Multiforme



Erythema Multiforme

- Triggers
 - HSV
 - *Mycoplasma pneumoniae*
 - Drugs

Erythema Multiforme

- Eruption is symmetric
 - Any area of body
 - Often on palms/soles
 - Appears over 3-7 days
- Fixed for several days
- Usually asymptomatic
 - Slight burning/itching

Erythema Multiforme

- Up to 50% with oral lesions (mild)
 - Swelling/crusting of lips
 - Erosions on tongue/buccal mucosa
 - Must have 2 or more mucous membranes for SJS!
- Lesions heal over 2-3 weeks
 - Post-inflammatory pigmentary changes

Erythema Multiforme

- Treatment is largely symptomatic
 - Oral antihistamines
 - Domeboro's soaks
 - Bland emollient
- Close monitoring for progression
- Steroids not indicated

What About “Serum Sickness?”

- Very rare in children
- Type III hypersensitivity rxn
 - Immune complex deposition
 - Complement activation
- Occurs within 1-3 weeks
 - animal serum or other foreign protein(s)

“Serum Sickness”

- Cutaneous features
 - Fixed urticarial eruption, angioedema, and a purpuric eruption on the edges of hands/feet
- Systemic inflammation
 - Vasculitis, nephritis, arthritis/arthralgia, myalgia, LAD

Serum Sickness Like Reaction (SSLR)

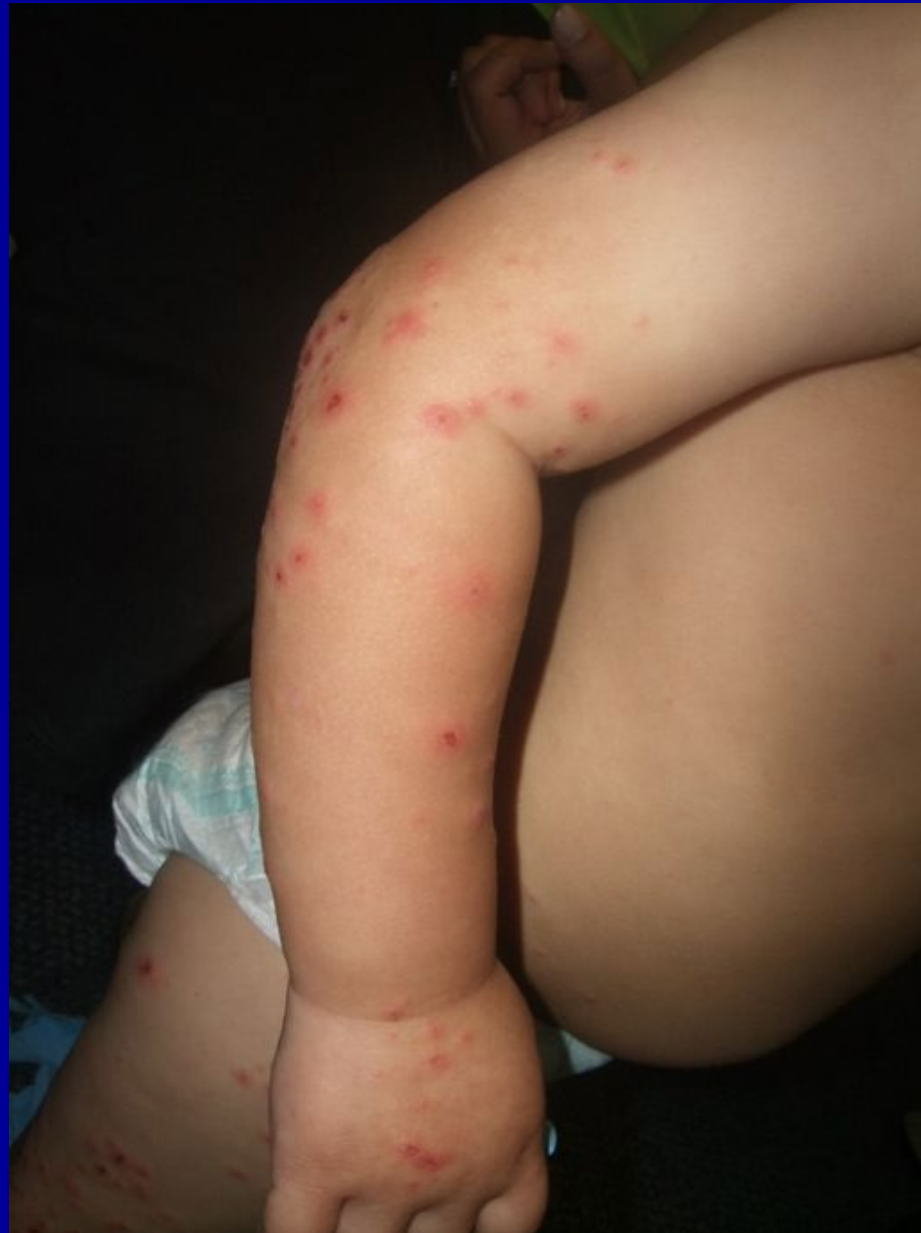- Fever, LAD, arthritis/arthralgia, angioedema, fixed urticarial eruption
- Triggers
 - Medications
 - Cefaclor, other
 - Pneumococcal vaccine

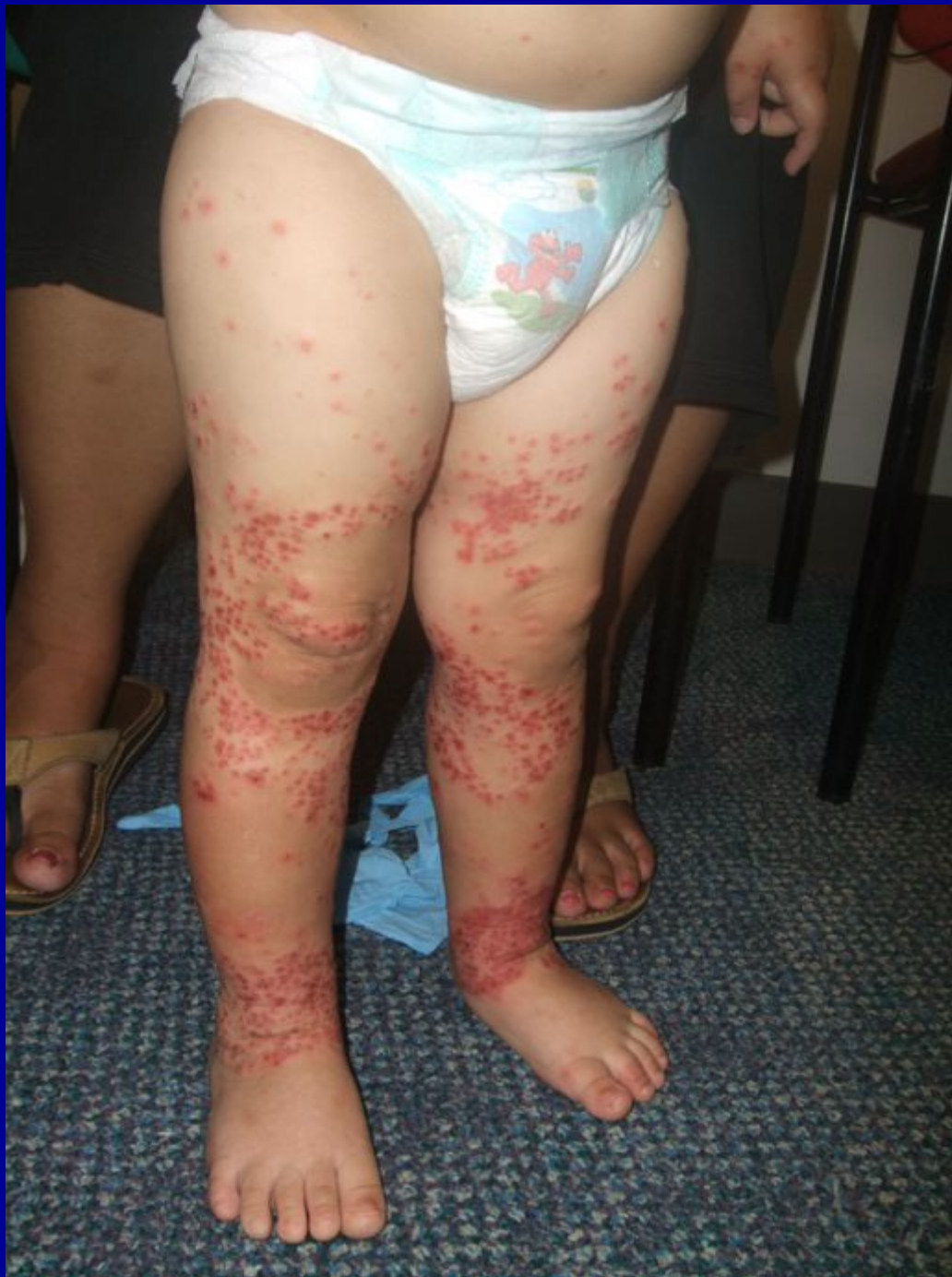SSLR

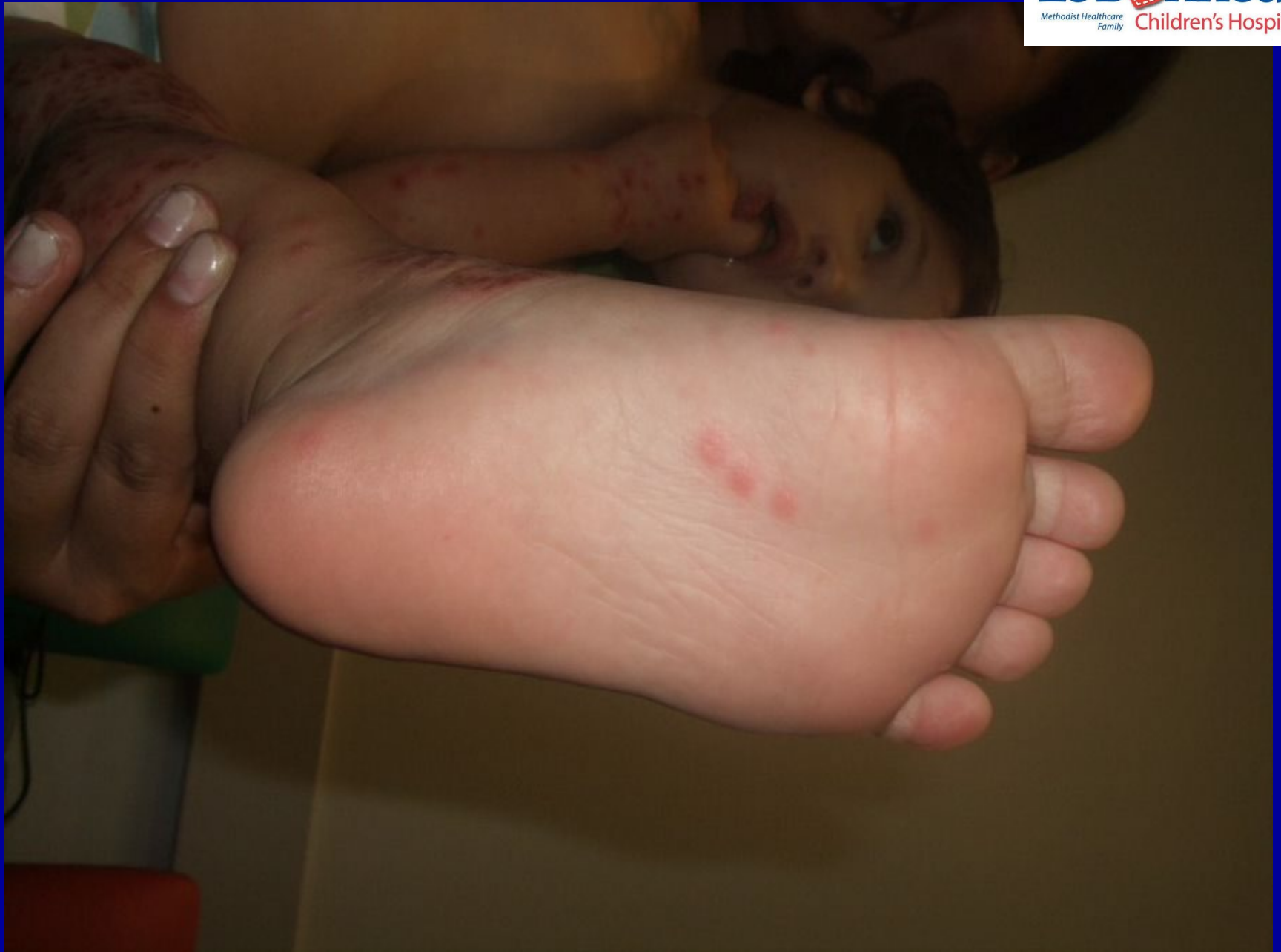- Treatment
 - d/c medication
 - Systemic antihistamines
 - Systemic steroids

Case #6

- 2 yr old healthy male
- Spent his first week at daycare.
- Now has a fever and diffuse rash of small erythematous macules and papules on the lower face, trunk, arms, and legs.







Diagnosis?

- a) Eczema herpeticum
- b) Varicella
- c) Atypical HFM
- d) Impetigo

Atypical HFM

- Classic HFM
 - CV A16, EV 71
 - Fever, malaise, herpangina
 - Rash
 - Papules, vesicles
 - Palms, soles, distal extremities, buttocks

Atypical HFV

- Coxsackie A6
 - Mild viral illness
 - Rash
 - Papules, vesicles, bullae, petechiae/purpura
 - Gianotti Crosti-like distribution
 - Cheeks, buttocks, extensors
 - “Eczema coxsackium”

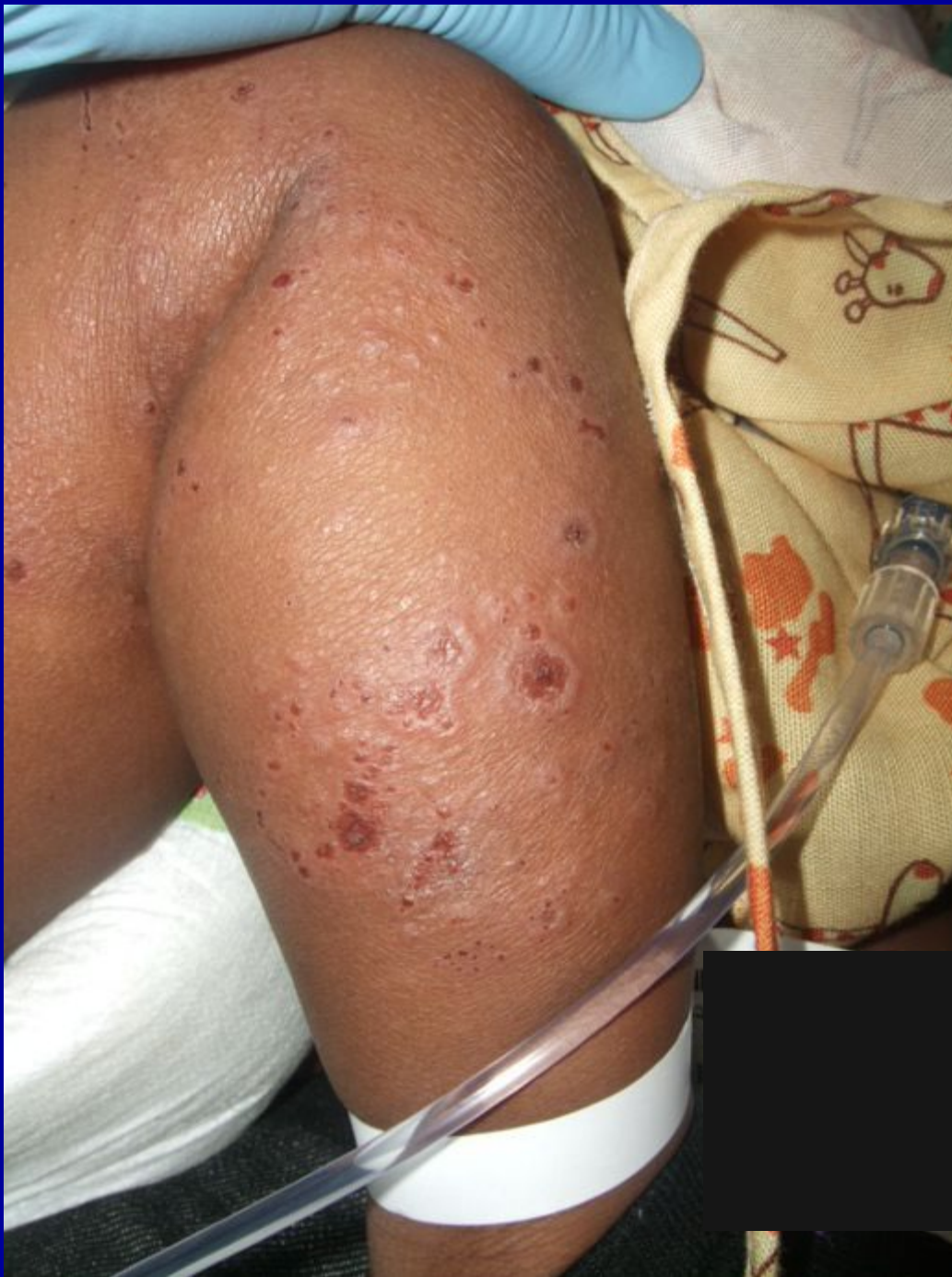Ventarola D et al. Clinics in Dermatology 2015 (33): 340-346.

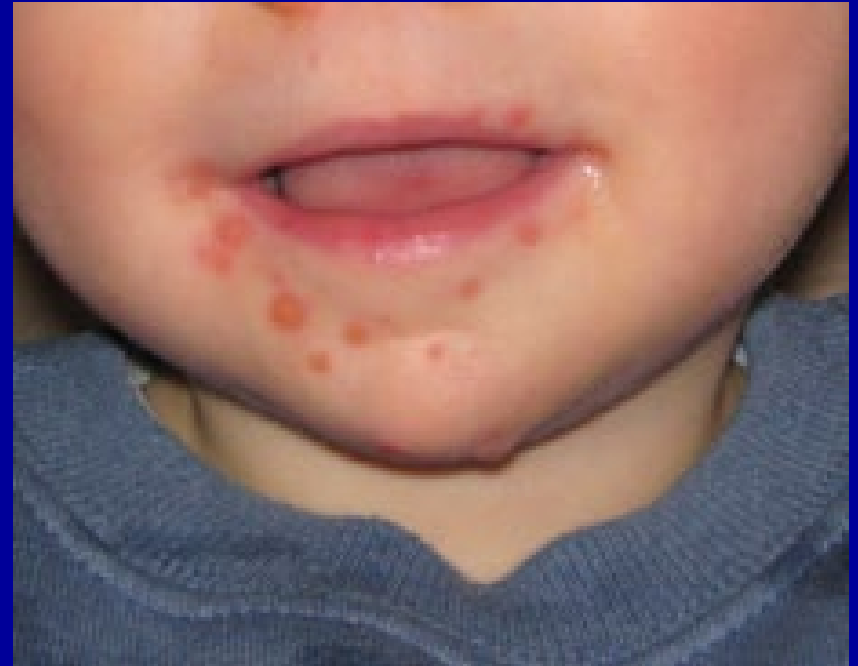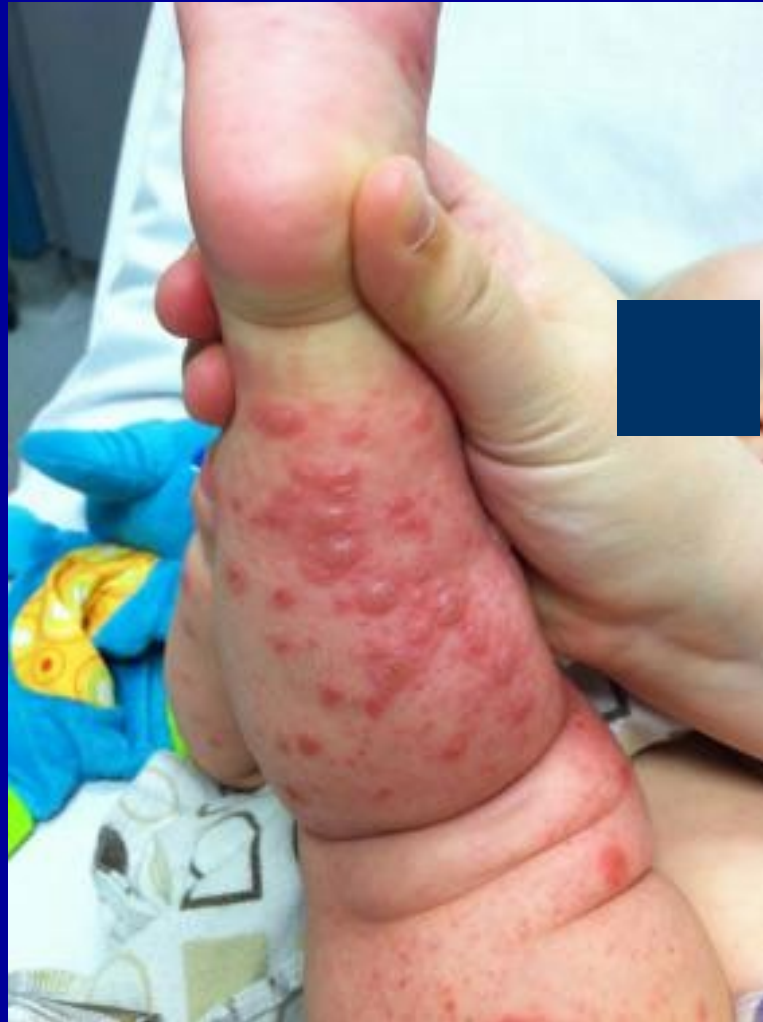Atypical HFMD

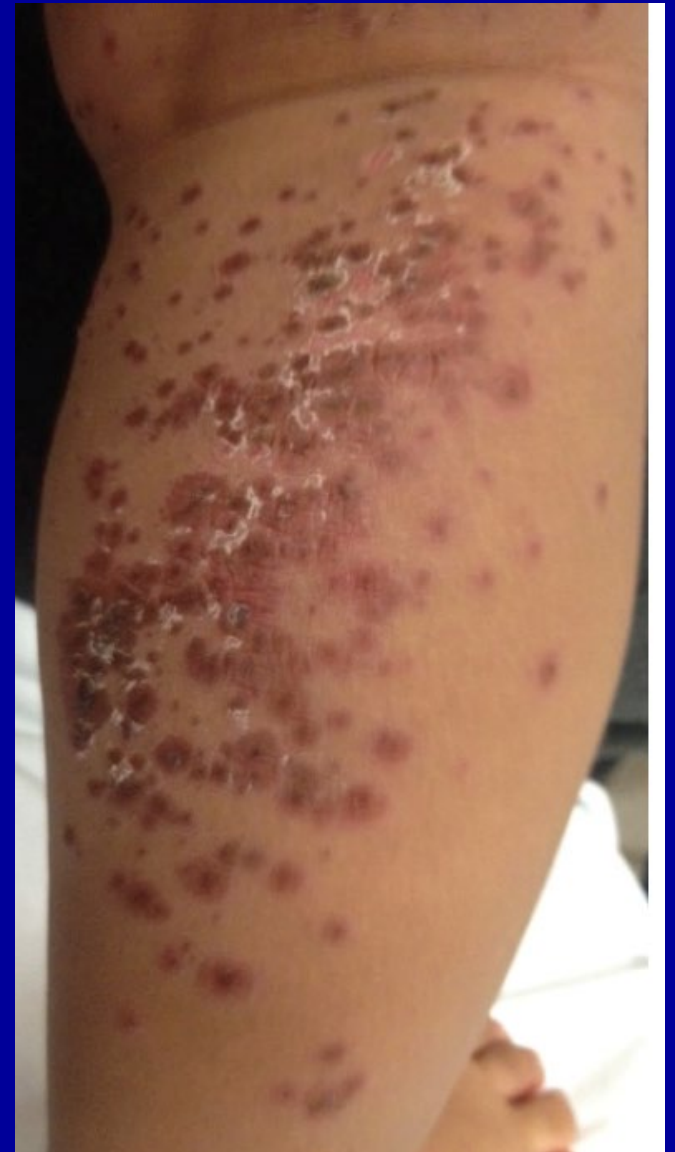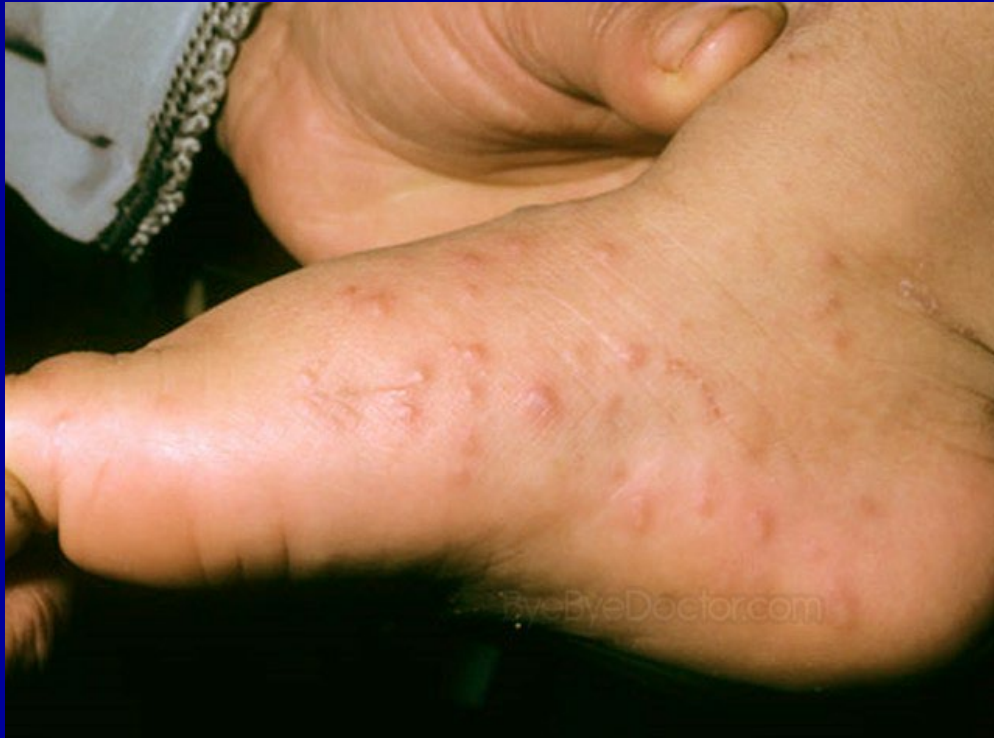- Transmission
 - Fecal/oral, oral/oral, respiratory
- Incubation
 - 3 to 6 days
- Viral shedding
 - Stool
 - 4 to 8 weeks

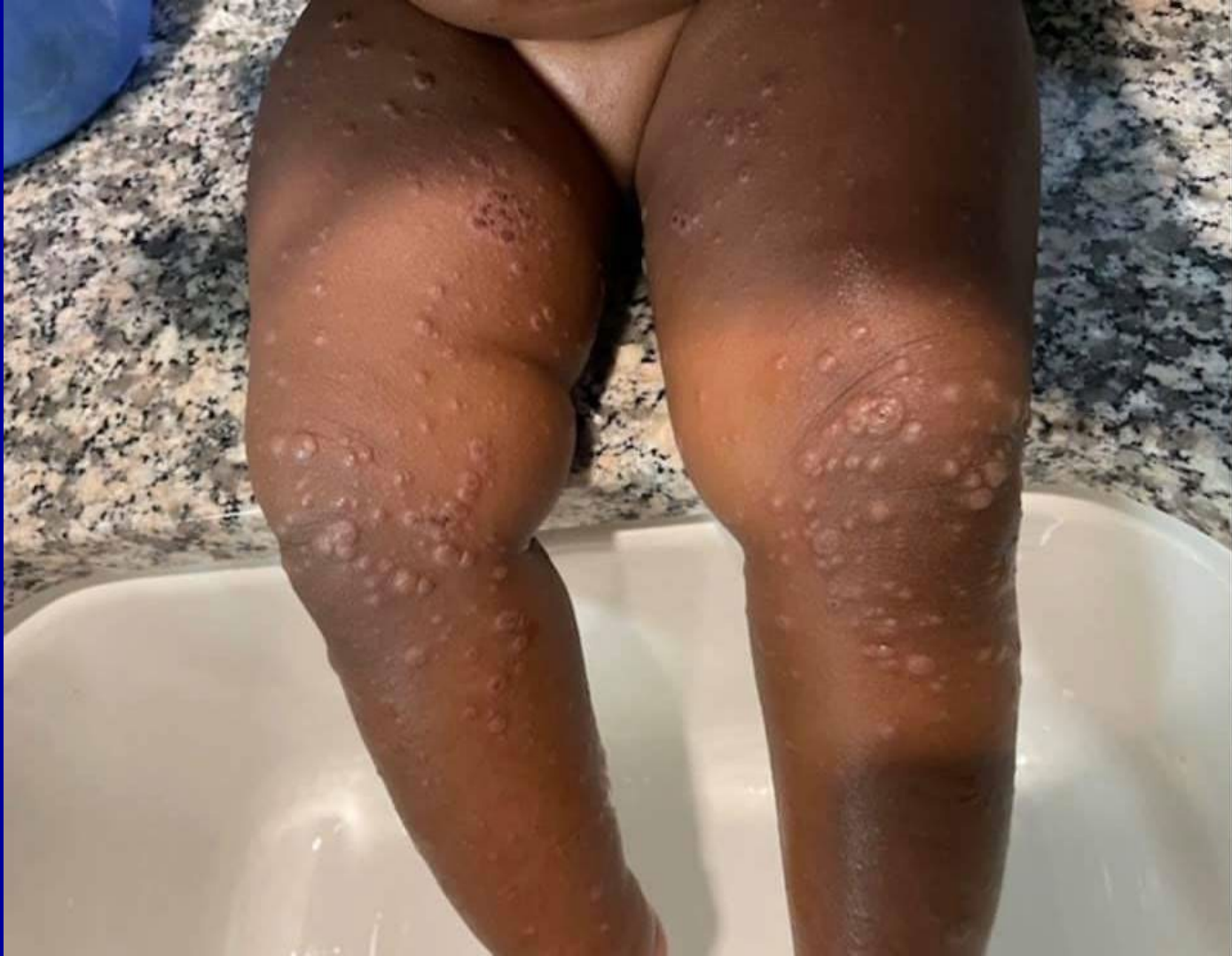Atypical HFV

- Course
 - 1 to 2 weeks
- Treatment
 - supportive

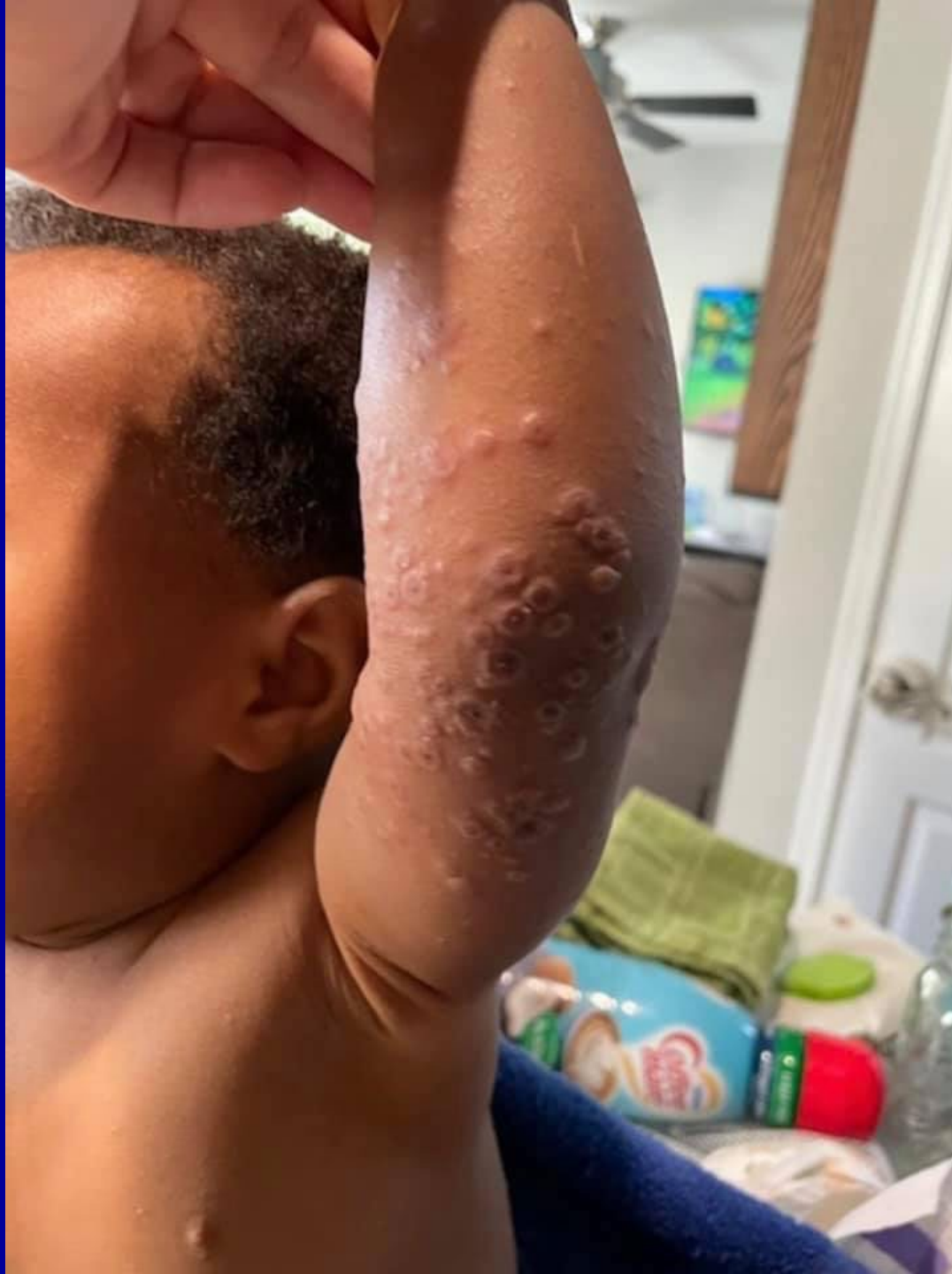


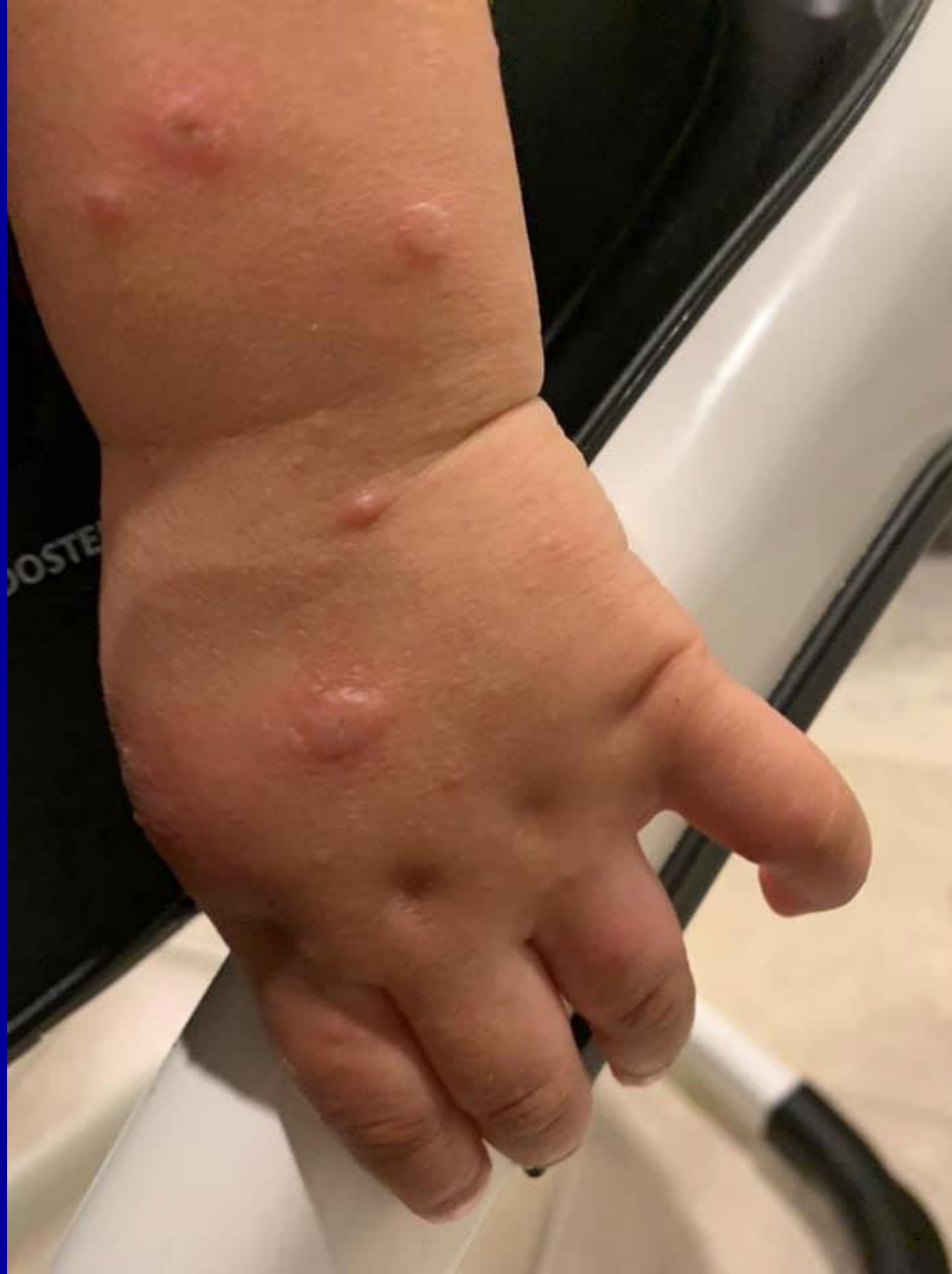


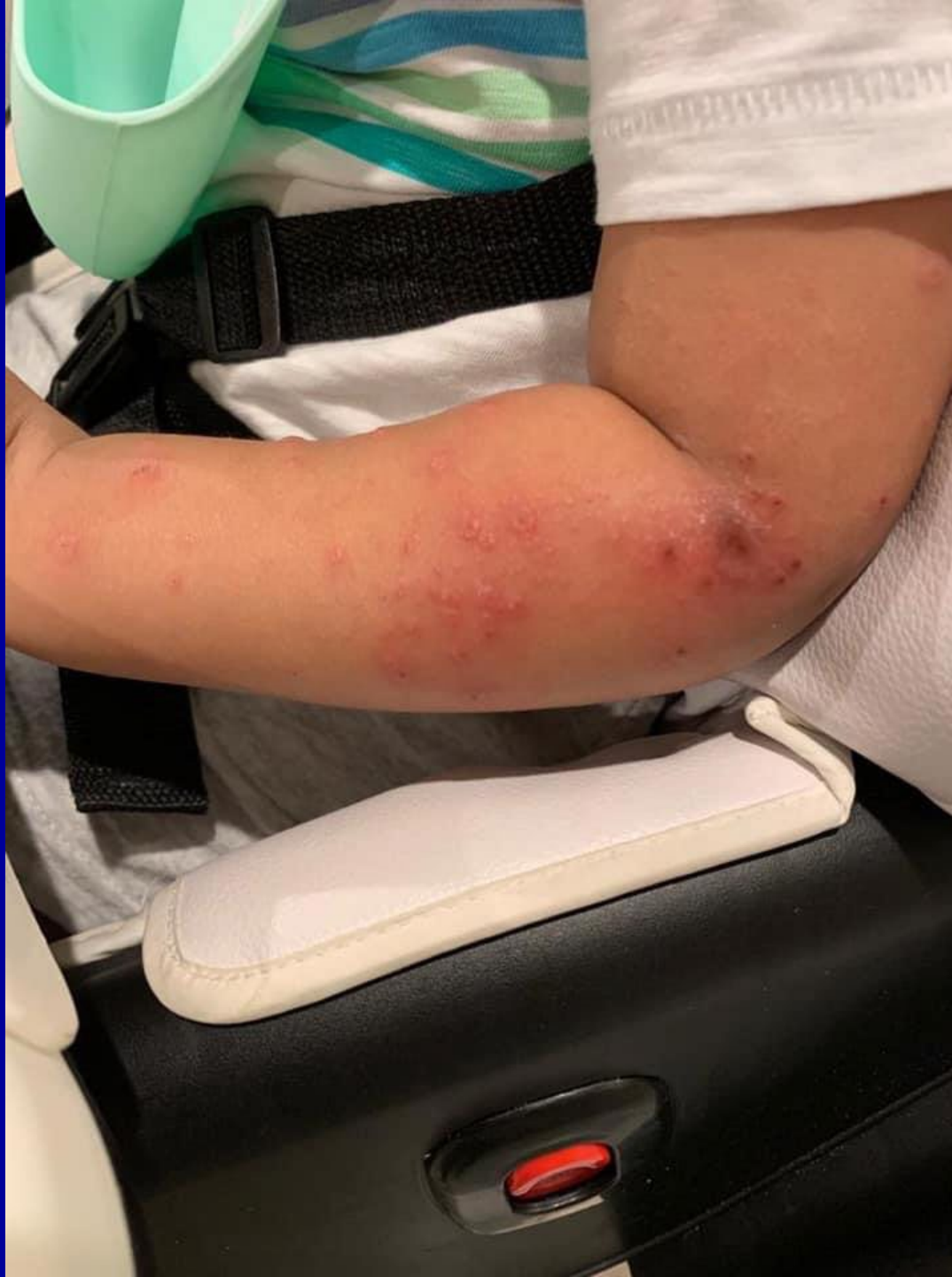


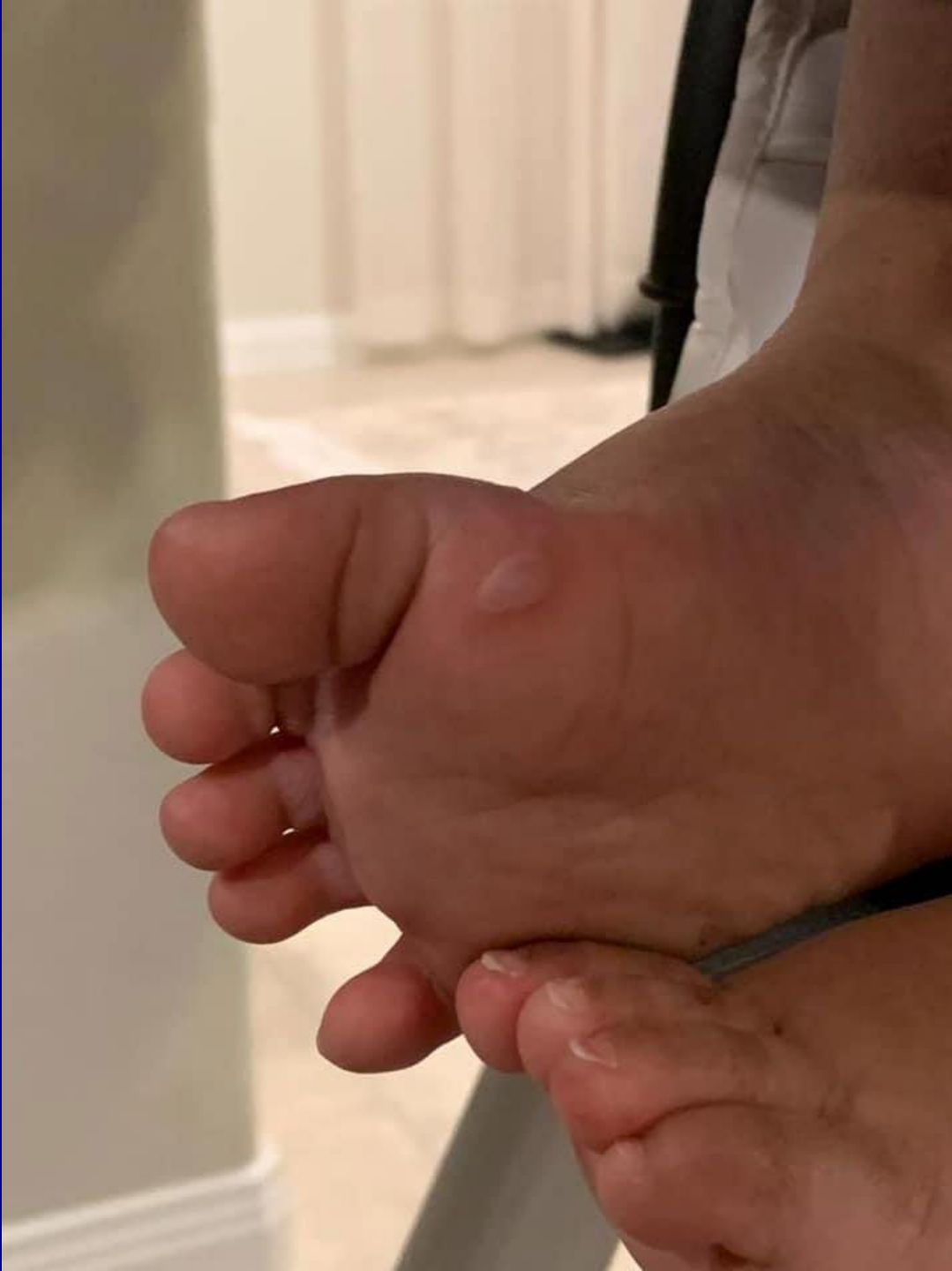


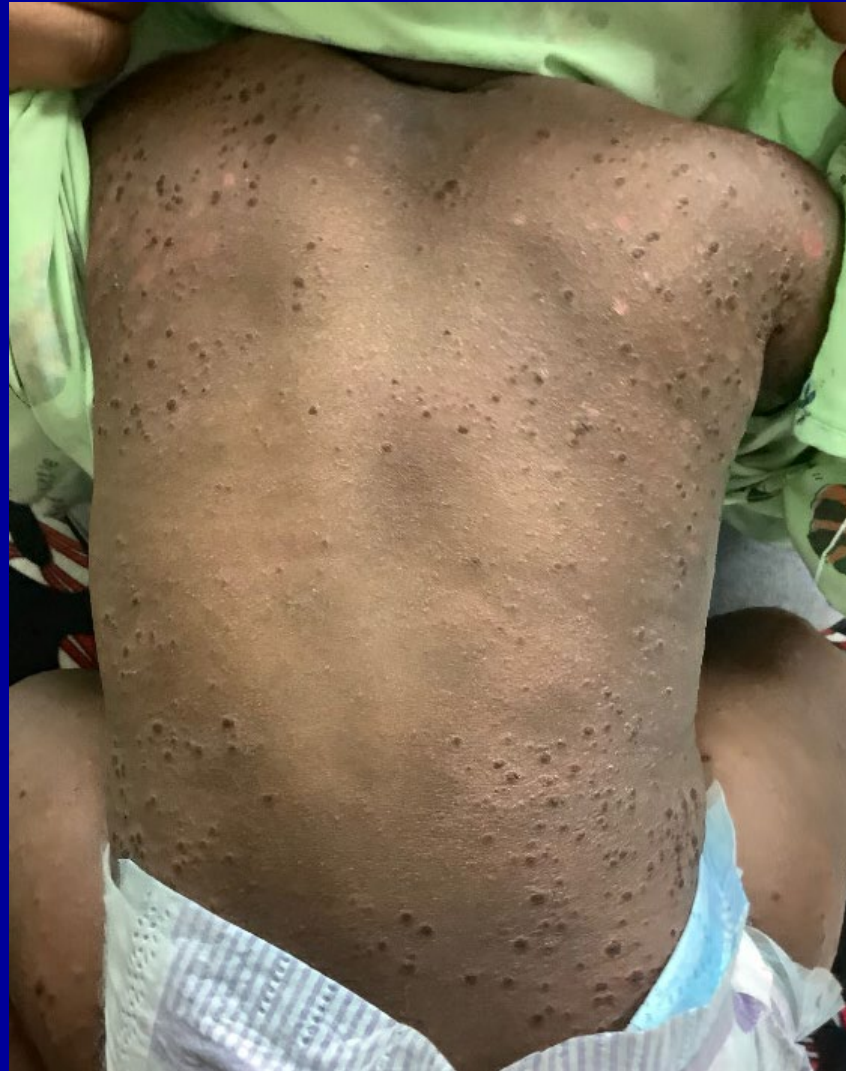


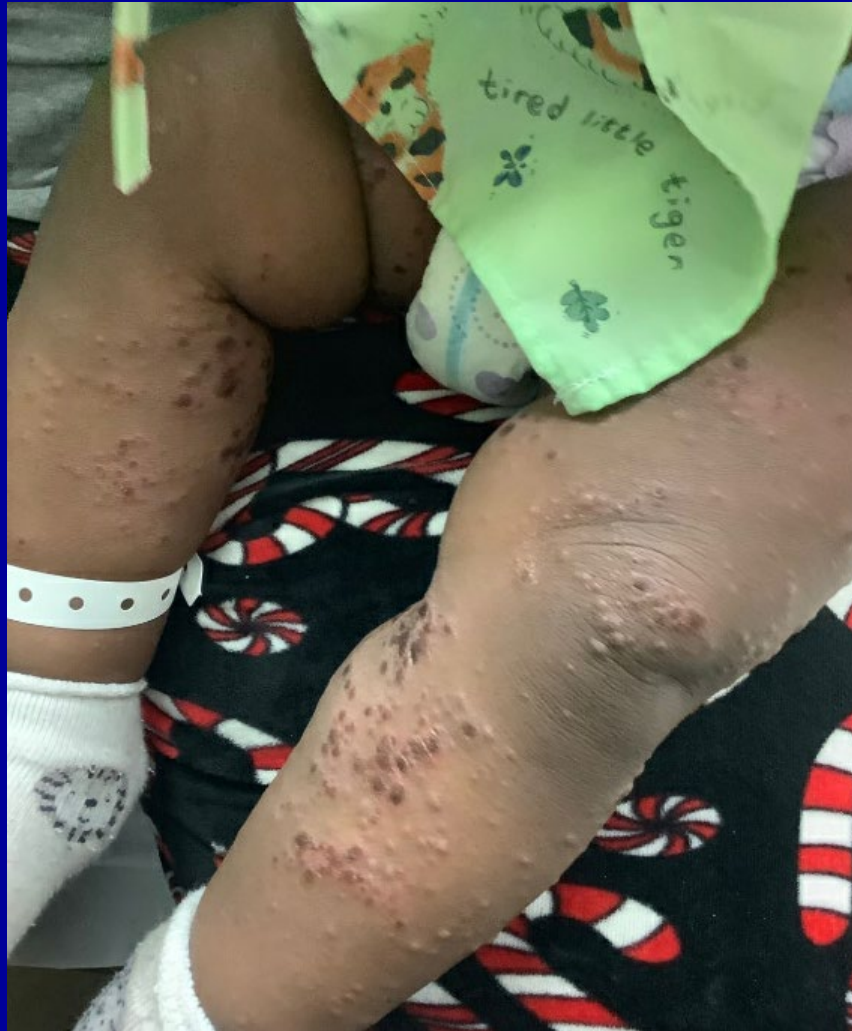


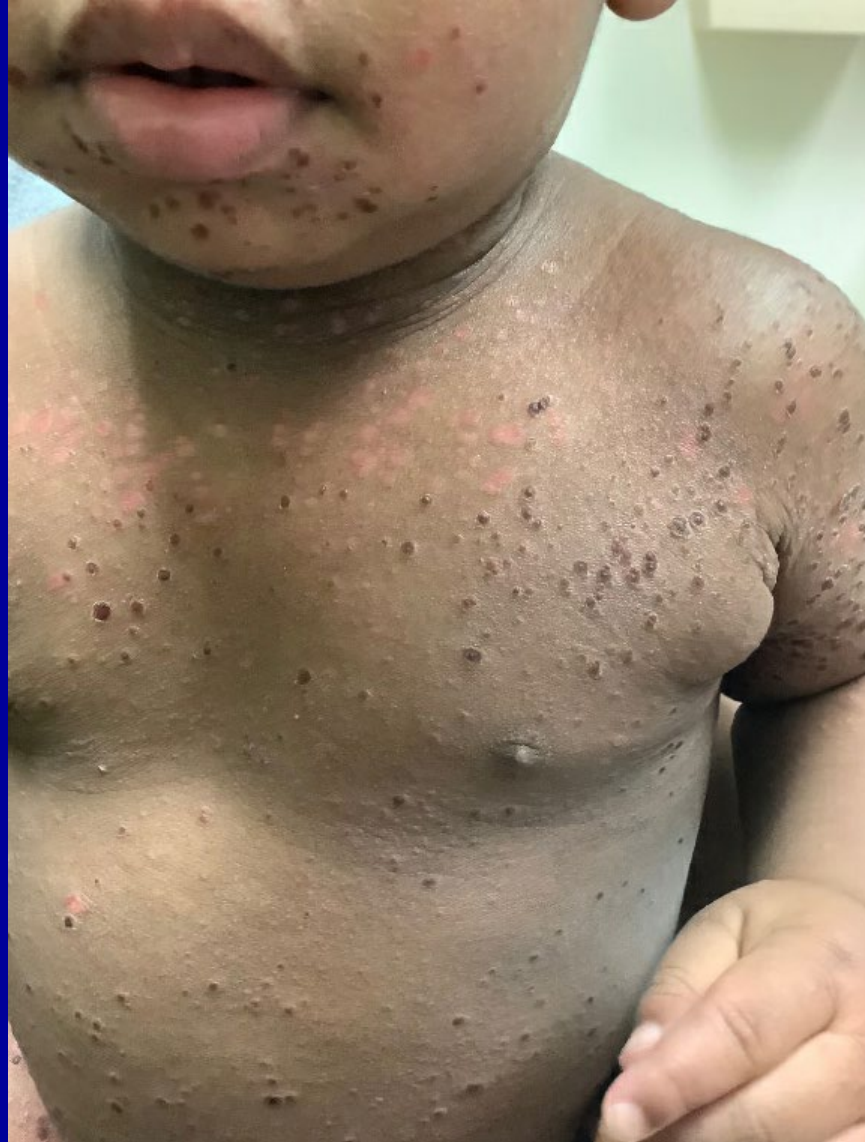


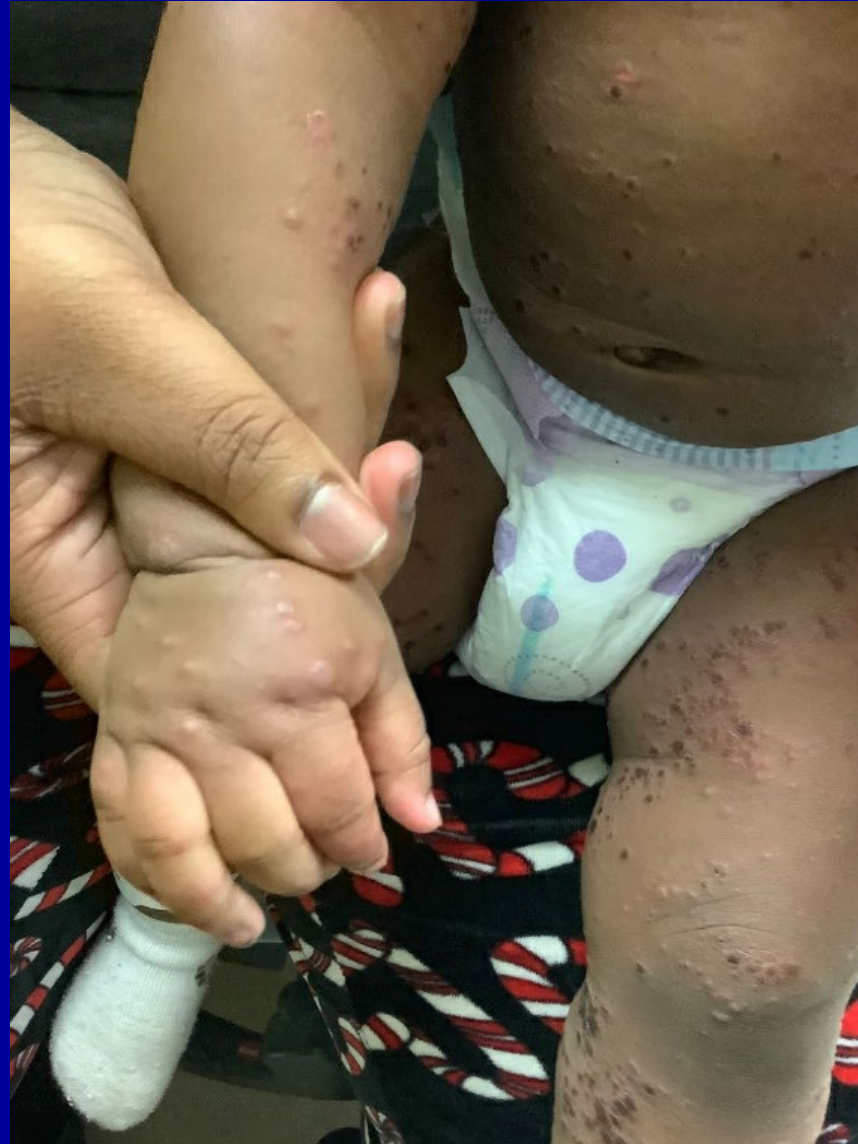




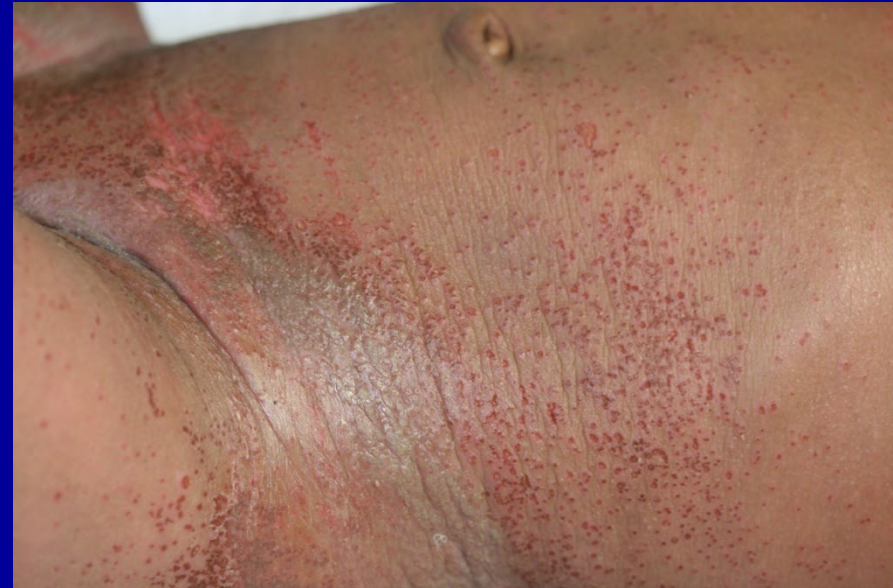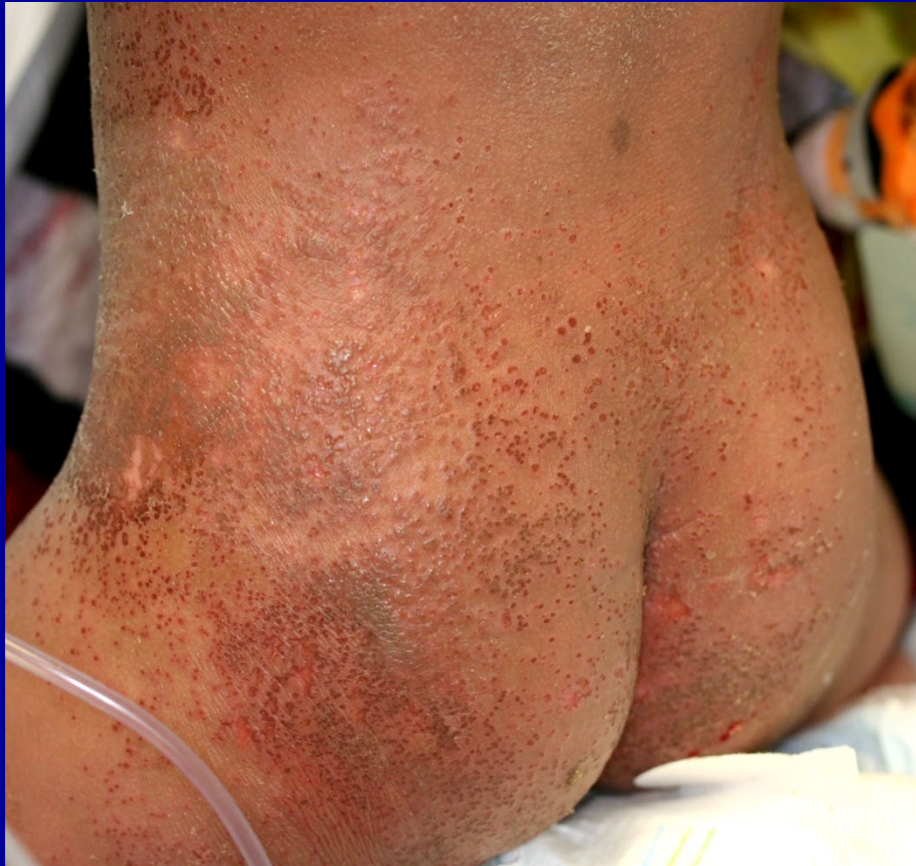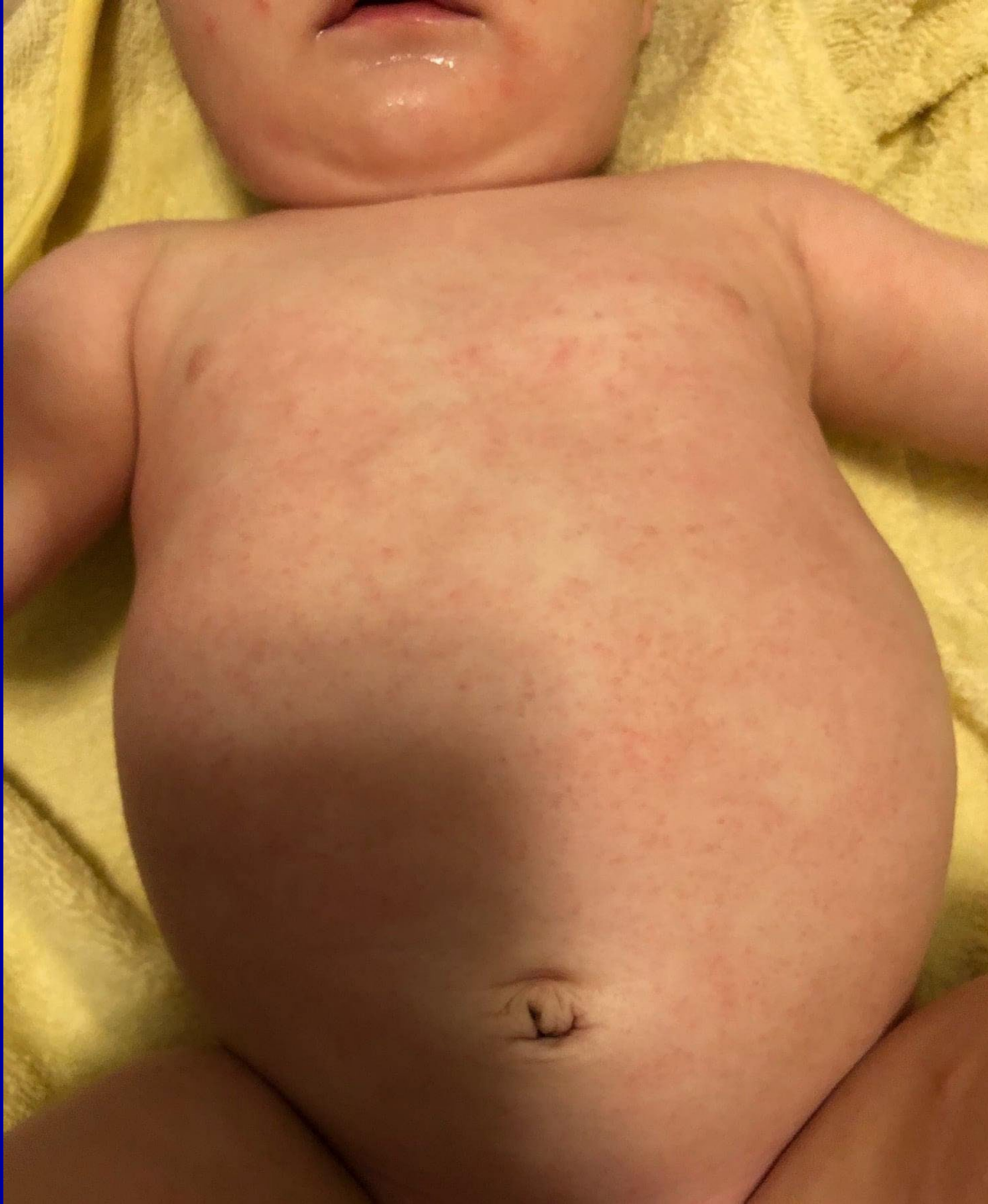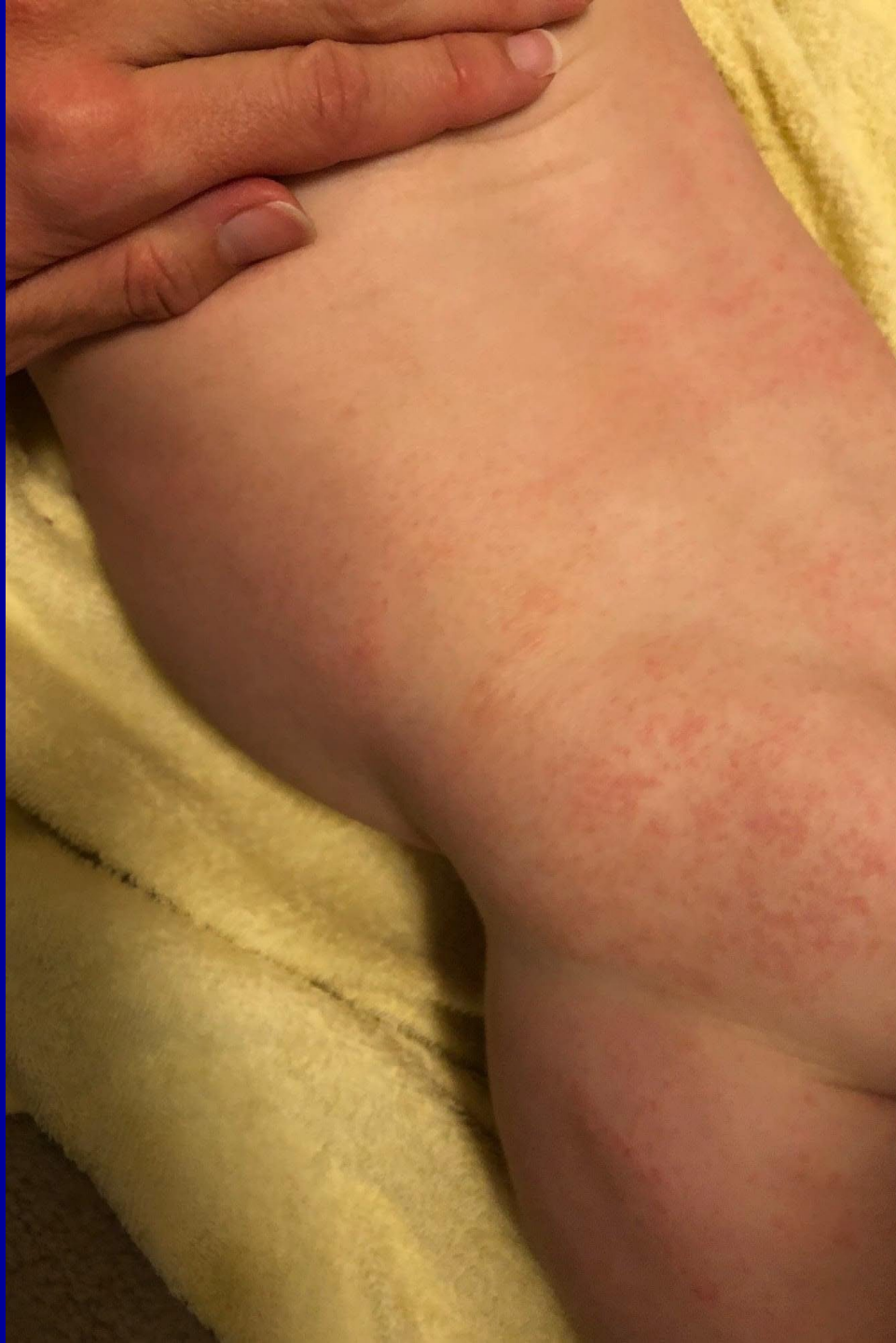Eczema herpeticum

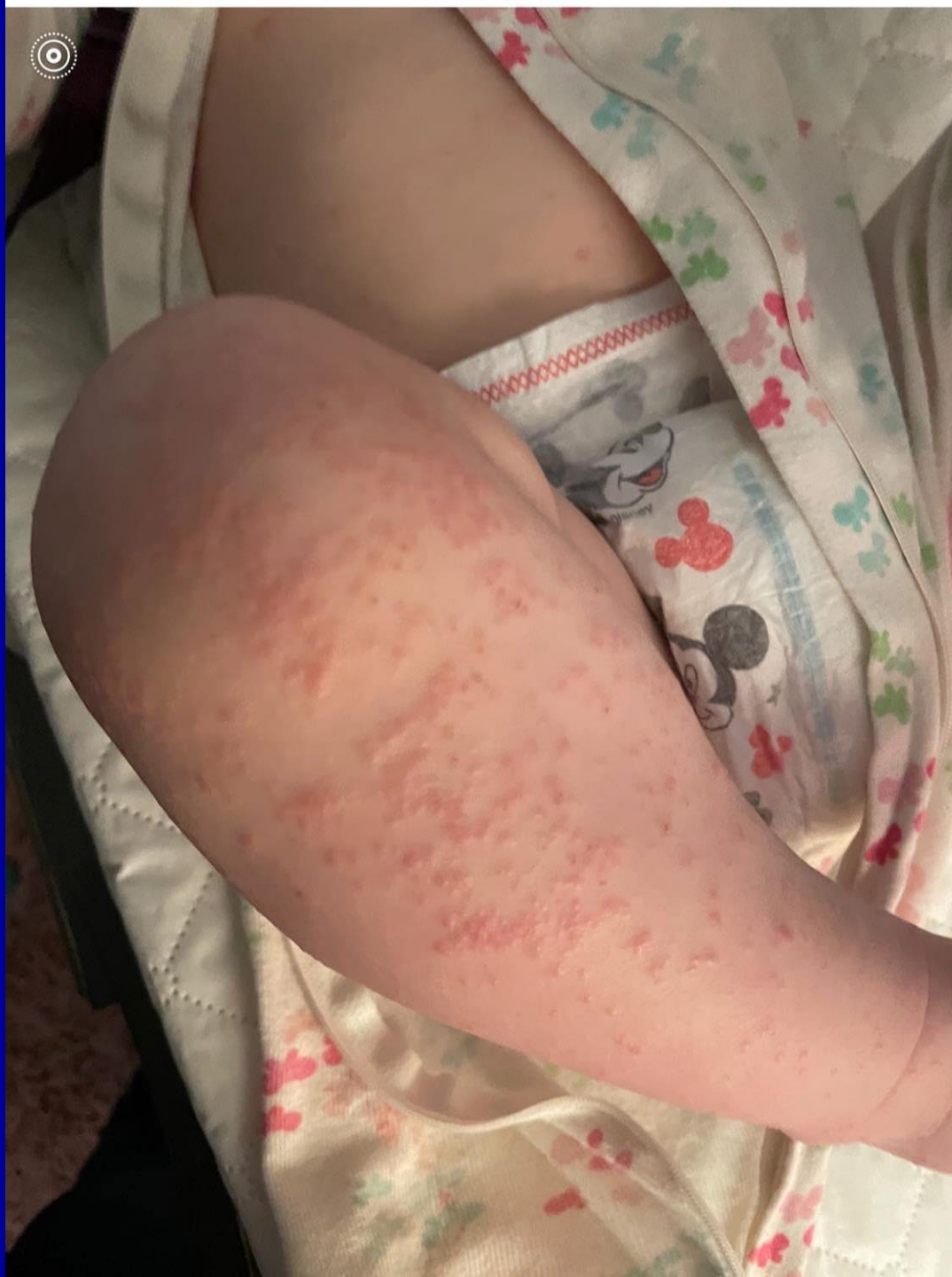

Not Sure?

- Serious vs. Not Serious
- Serious
 - Mucous membranes?
 - Signs of necrosis/impending necrosis?
 - Systemic involvement?
 - Does child look very ill?







Not Sure?

- Probably Not Serious
 - SDV (some d*** virus)
 - Treat symptoms
 - Give it some time
- Most will either resolve or declare themselves.

Thank You!

- twrigh43@uthsc.edu